

PREVALENCE, PATHOLOGY, AND RISK FACTORS ASSOCIATED WITH *STREPTOCOCCUS PHOCAE* INFECTION IN SOUTHERN SEA OTTERS (*ENHYDRA LUTRIS NEREIS*), 2004–2010

Georgina Bartlett,^{1,2} Woutrina Smith,³ Clare Dominik,¹ Francesca Batac,¹ Erin Dodd,¹ Barbara A. Byrne,⁴ Spencer Jang,⁵ David Jessup,¹ Julian Chantrey,² and Melissa Miller^{1,3,6}

¹ Marine Wildlife Veterinary Care and Research Center, California Department of Fish and Wildlife, 1451 Shaffer Road, Santa Cruz, California 95060, USA

² National Centre for Zoonosis Research, University of Liverpool, School of Veterinary Science, Leahurst Campus, Chester High Road, Neston CH64 7TE, UK

³ Wildlife Health Center, School of Veterinary Medicine, University of California, Davis, 1089 Veterinary Medicine Drive, Davis, California 95616, USA

⁴ Department of Pathology, Microbiology and Immunology, School of Veterinary Medicine, University of California, Davis, One Shields Avenue, Davis, California 95616, USA

⁵ William R. Pritchard Veterinary Medical Teaching Hospital, School of Veterinary Medicine, University of California, Davis, 1 Garrod Drive, Davis, California 95616, USA

⁶ Corresponding author (email: Melissa.Miller@wildlife.ca.gov)

ABSTRACT: Recent studies have implicated beta-hemolytic streptococci as opportunistic pathogens of marine mammals, including southern sea otters (*Enhydra lutris nereis*), but little is known about their prevalence or pathophysiology. Herein, we focus on risk factors for sea otter infection by a single beta-hemolytic streptococcal species, *Streptococcus phocae*. *Streptococcus phocae* was first identified as a marine mammal pathogen in 1994, and the first report in southern sea otters was in 2009. Its broad host range encompasses fish, pinnipeds, cetaceans, and mustelids, with *S. phocae* now recognized as an important pathogen of marine species worldwide. We assessed risk factors and lesion patterns for *S. phocae* infection in southern sea otters. Using archival necropsy data, *S. phocae* prevalence was 30% in fresh dead otters examined 2004–2010. Skin trauma of any type was identified as a significant risk factor for *S. phocae* infection. The risk of infection was similar regardless of the cause and relative severity of skin trauma, including mating or fight wounds, shark bite, and anthropogenic trauma. *Streptococcus phocae*-infected sea otters were also more likely to present with abscesses or bacterial septicemia. Our findings highlight the importance of *S. phocae* as an opportunistic pathogen of sea otters and suggest that the most likely portal of entry is damaged skin. Even tiny skin breaks appear to facilitate bacterial colonization, invasion, abscess formation, and systemic spread. Our data provide important insights for management and care of marine species.

Key words: Abscess, beta-hemolytic streptococci, mating trauma, sepsis, skin wound, southern sea otter (*Enhydra lutris nereis*), *Streptococcus phocae*.

INTRODUCTION

The southern sea otter (*Enhydra lutris nereis*) is a federally listed threatened species that inhabits the coastline of central California, USA. Despite 100 yr of legal protection, this population has been slow to expand, in part, due to high mortality and habitat limitations. Many otters die following exposure to opportunistic pathogens, including land-based parasites and fungi. Although much has been learned about terrestrial pathogens of sea otters, little is known about the pathogenicity of marine and estuarine bacteria that infect this species.

Bacterial streptococci are common pathogens of terrestrial animals and humans (Henton et al. 1999). *Streptococcus* spp. are classified by their hemolytic properties on conventional blood agar as alpha-, beta-, or gamma-hemolytic. Beta-hemolytic streptococci are further subdivided via Lancefield serotyping, based on carbohydrate expression on the bacterial cell wall. Twenty serotypes span Lancefield groups A through V (excluding I and J), with some association between Lancefield grouping, host range, and disease expression.

In human medicine, key pathogens include alpha- and beta-hemolytic streptococci of Lancefield groups A and B.

Human diseases associated with infection by group A streptococci include streptococcal pharyngitis (strep throat), toxic shock syndrome, necrotizing fasciitis, pneumonia, septicemia, and rheumatic fever. Infection by group B streptococci can trigger pneumonia, meningitis, and septicemia, especially in the elderly and neonates. Group B streptococci also infect terrestrial and aquatic animals, including camels (*Camelus dromedaries*; Fischer et al. 2013), dogs (*Canis lupus familiaris*; Lamm et al. 2010), cats (*Felis catus*; Tillman et al. 1982), crocodiles (*Crocodylus porosus*; Bishop et al. 2007), and fish (Kusuda and Kawai 1982; Gonzales-Contreras et al. 2011). In exposed animals, group B streptococci can be significant veterinary pathogens, causing mastitis (Keefe 1997), pyometra (Hueffer et al. 2011), abscesses (Imai et al. 2009), and septicemia (Burek et al. 2005).

Streptococci are recognized as important marine mammal pathogens. Infection by *Streptococcus infantarius* subsp. *coli* and other pathogenic streptococci has been associated with fatal vegetative valvular endocarditis, septicemia, and thromboembolic disease in southern and northern (*Enhydra lutris kenyoni*) sea otters, especially for otters stranding in Alaska (Burek et al. 2005; Counihan-Edgar et al. 2012). More recently, the facultatively anaerobic, beta-hemolytic, pyogenic bacterium *Streptococcus phocae* (Skaar et al. 1994; Romalde et al. 2008) has been reported from numerous marine animals. First reported from harbor seals (*Phoca vitulina*) with pneumonia in northwestern Europe (Skaar et al. 1994), *S. phocae* is now recognized as an opportunistic pathogen for marine species worldwide, including grey seals (*Halichoerus grypus*; Vossen et al. 2004), ringed seals (*Phoca hispida*; Romalde et al. 2008), Cape fur seals (*Arctocephalus pusillus pusillus*; Henton et al. 1999), Caspian seals (*Pusa caspica*; Imai et al. 2009), spotted seals (*Phoca largha*; Hueffer et al. 2011), and California sea lions (*Zalophus californianus*; Johnson et al.

2006). *Streptococcus phocae* has also been isolated from a harbor porpoise (*Phocoena phocoena*; Romalde et al. 2008) and farmed Atlantic salmon (*Salmo salar*), with mortality rates as high as 25% (Romalde et al. 2008). Although *S. phocae* can be isolated from the respiratory and gastrointestinal tracts of healthy marine animals (Imai et al. 2009; Miller et al. 2010), infection is commonly associated with pneumonia and septicemia (Henton et al. 1999), neoplasia (Johnson et al. 2006), opportunistic infections (Imai et al. 2009), and pyometra (Hueffer et al. 2011).

In southern sea otters, *S. phocae* infection was first identified during studies of bacterial flora (Imai et al. 2009). Most sea otter-derived, beta-hemolytic streptococci expressed group G, F, and C Lancefield surface antigens. Some additional sea otter isolates were untypeable via the Lancefield system but were assigned to *S. phocae* by using molecular characterization (Imai et al. 2009). However, despite the wide geographic distribution of *S. phocae* and its broad host range, potential environmental sources, routes of infection, and common case presentations were unreported (Gonzalez-Contreras et al. 2011).

A study of the adherence and invasion properties of *S. phocae* isolates from salmon revealed nonspecific adherence to eukaryotic cells but limited ability to invade intact tissue (Gonzalez-Contreras et al. 2011), suggesting that skin wounds and other breaks in host defenses could facilitate *S. phocae* infection in salmonids. Based on these reports, we predicted that *S. phocae* infection would be common in southern sea otters and would be associated with dermal or mucous membrane lesions. Wounds sustained during fights, copulation, and predation are common in sea otters (Staedler and Riedman 1993; Kreuder et al. 2003), providing a portal for *S. phocae* infection. Breaks in mucosal barriers lining the respiratory, gastrointestinal, and urogenital tracts might also facilitate infection and systemic spread. We determined the prevalence of *S. phocae*

infection in southern sea otters by reviewing retrospective necropsy records from 2004 through 2010. Our findings highlight the importance of *S. phocae* as an opportunistic pathogen of sea otters. We also identify the most likely route of infection and describe *S. phocae*-associated lesions in sea otters. Our findings will inform care and management of diverse marine species, especially threatened sea otters.

MATERIALS AND METHODS

Case selection and *S. phocae* detection

Enrolled southern sea otters included fresh (<72 h postmortem under refrigeration) animals from central California with full necropsies performed at the Marine Wildlife Veterinary Care and Research Center. Cases were defined as *S. phocae*-positive otters that were not treated with antibiotics prior to euthanasia or death and had at least one aerobic bacterial isolate cultured from lesions, tissue, internal fluids, digesta, or feces following necropsy. Controls satisfied the previously mentioned selection criteria, except that they were culture negative for *S. phocae* and related beta-hemolytic streptococci. Cases were excluded from the study if detailed necropsy or risk factor data were unavailable and if bacterial isolate identity as *S. phocae* was undetermined. Fetuses were excluded due to lack of exposure to most trauma types that were being assessed and the absence of a fully formed immune response. Sea otters necropsied prior to 2004 were also excluded due to lower precision of detection and identification of beta-hemolytic streptococci and *S. phocae*.

Swabs for bacterial culture were maintained on Amies transport medium (Becton, Dickinson and Company, Sparks, Maryland, USA), cooled, and mailed overnight to the University of California Davis (UCD) Veterinary Medical Teaching Hospital for bacterial isolation and identification by using standard media and enrichment techniques (Miller et al. 2010). Inoculated sheep blood agar plates (UCD Biological Media Service, Davis, California, USA) were incubated aerobically at 35 C in 5% CO₂ for up to 5 d. Small beta-hemolytic colonies staining as gram-positive cocci were selected for further biochemical identification. *Streptococcus phocae* isolates were further characterized by the presence of a soluble hemolysis in sheep blood broth (UCD Biological Media Service), a negative catalase test, lack of utilization of lactose, sorbitol, or trehalose, and agglutination to Lancefield groups C, F, or G antiserum. A subset of

isolates was also characterized by using an API Strep Identification Kit (BioMérieux, Hazelwood, Missouri, USA). We performed PCR amplification and partial sequencing of 16S ribosomal DNA on isolates that gave uncertain biochemical testing results (Miller et al. 2010).

Characterization of risk factors and data analysis

Potential risk factors for *S. phocae* infection were defined for each case, including sex (male or female), age (immature: pups, juveniles, and subadults; adult: adults and aged adults), year (sample years 2004 to 2010: year 1 through year 7, respectively), and season (dry season: April through October; wet season: November through March). Breaks in host defenses were defined as grossly apparent, acute to subacute skin trauma (external lesions), or antemortem perforations of the gastrointestinal, respiratory, or urogenital mucosa (internal lesions) that were documented in necropsy reports and photographs. Trauma type was categorized as mating or fighting trauma; great white shark (*Carcharodon carcharias*) predation; and anthropogenic trauma, such as boat strike, gunshot, or fishing line or hook entanglement. Associations between culture-confirmed *S. phocae* infection and detection of abscesses or septicemia at necropsy were also evaluated as described in the following.

The prevalence of *S. phocae* infection in sea otters was estimated as the number of *S. phocae* cases divided by the total number of animals tested in the study population. Univariable and multivariable logistic regression approaches were used in a forward-stepping manner to investigate associations between risk factors and *S. phocae* detection. First, each risk factor or observed lesion was evaluated individually in relation to *S. phocae* detection (or absence). Then logistic regression models were used to produce adjusted odds ratios that measured the strength of associations for multiple risk factors on the odds of *S. phocae* detection in the multivariable model. $P < 0.05$ was considered statistically significant.

RESULTS

Case selection and *S. phocae* detection

Necropsied sea otters consisted of 90 *S. phocae*-positive cases and 132 culture-negative controls (Table 1). Both groups were broadly distributed across sample years and seasons (wet or dry season), and both contained approximately equal numbers of

TABLE 1. Risk factors and lesion characteristics for necropsied, *Streptococcus phocae*-infected southern sea otter (*Enhydra lutris nereis*) cases, compared with *S. phocae*-negative controls (central California, USA, 2004–2010).

Risk factor category	No. of cases	% cases	No. of controls	% controls
Break in host external or skin or internal or mucosal defenses				
Yes	82	90	95	72
No	9	10	37	28
Location of break in host defenses				
External	35	38	28	21
Internal	14	15	49	37
Both	33	36	18	14
None	9	10	37	28
Trauma type				
Mating or fight	44	48	25	19
Shark	17	19	14	11
Anthropogenic	9	10	10	8
None	21	23	83	63
Abscesses identified at necropsy				
Yes	42	46	19	14
No	49	54	113	86
Sepsis identified at necropsy				
Yes	59	76	55	42
No	32	35	77	58
Sex				
Male	51	56	80	61
Female	40	44	52	39
Age				
Immature	23	25	56	42
Adult	68	75	76	58
Sample year				
2004	14	15	30	23
2005	12	13	22	16
2006	19	21	38	28
2007	17	19	20	15
2008	9	10	10	13
2009	7	8	8	6
2010	13	14	4	3
Season				
Wet	32	35	51	39
Dry	59	65	81	61

males and females (Table 1). Both *S. phocae* and untypeable beta-hemolytic streptococci were isolated from the same sample for two cases, indicative of concurrent infection. Eighty-four *S. phocae*-positive otters were cultured at greater than one sample site, and 60% ($n=50$) were *S. phocae*-positive at more than one site.

Of 90 *S. phocae*-positive otters, 75% ($n=68$) had skin lesions at the time of necropsy, 65% ($n=59$) were diagnosed with bacterial sepsis, and 47% ($n=42$) had bacterial abscesses, with 25% ($n=23$) of cases producing *S. phocae* from abscesses by culture. Of 23 otters with *S. phocae*-positive

abscesses, pure growth of *S. phocae* was noted for 10 animals (mainly lymph nodes, joints, and internal organs), while 13 abscesses produced mixed bacteria, including *S. phocae* (mainly external wounds and abscesses). Bacterial culture results often correlated with histopathology findings, with mixed bacteria apparent in skin wounds and abscesses, and a predominance of bacterial cocci in internal tissues.

Characterization of risk factors and data analysis

Cases contained a higher proportion of adults, while controls were more evenly

TABLE 2. Significant risk factors and lesion characteristics (univariable analyses) for *Streptococcus phocae* infection in southern sea otters (*Enhydra lutris nereis*) from central California, USA, necropsied from 2004 to 2010.

Risk factors (reference group)	Odds ratio	<i>P</i>	95% CI ^a
External or skin break in host defenses (no external break)	5.1	<0.001	2.8–9.0
Trauma type			
Intraspecific mating or fight trauma (no trauma)	6.6	<0.001	3.4–13.0
Shark trauma (no trauma)	4.9	<0.001	2.1–11.2
Anthropogenic trauma (no trauma)	3.2	0.023	1.2–8.9
Bacterial abscesses (no bacterial abscesses)	5.1	<0.001	2.7–9.6
Bacterial septicemia (no septicemia)	2.6	0.001	1.5–4.5
Immature otters (adults)	0.5	0.009	0.3–0.8
Otter stranding during 2010 (2004)	6.9	0.003	1.9–25.2

^a CI = confidence interval.

distributed between immature animals and adults. Cases also appeared to be overrepresented in the categories of external trauma, external breaks in host defenses, abscesses, and sepsis, when compared with controls. Significant associations for univariable analyses are summarized in Table 2. Factors that were not significantly associated with enhanced risk of *S. phocae* infection included sex ($P=0.495$), season of stranding ($P=0.54$), and internal breaks in host defenses ($P=0.95$).

Based on a multivariable logistic regression model that includes multiple risk factors, all forms of external (skin) trauma were significantly associated with *S. phocae* detection (Table 3). When compared with animals with no trauma, otters with intraspecific mating or fight trauma had 6.7 times greater odds ($P<0.001$), those with shark bite trauma had 8.4 times greater odds ($P<0.001$), and animals with anthropogenic trauma had 5.6 times greater odds ($P=0.005$) of *S. phocae* detection.

TABLE 3. Significant risk factors and lesion characteristics (multivariable analyses) for *Streptococcus phocae* infection in southern sea otters (*Enhydra lutris nereis*) from central California, USA, necropsied from 2004 to 2010.

Significant risk factors (reference group)	Odds ratio	<i>P</i> value	95% CI ^a
Trauma type			
Intraspecific mating or fight trauma (no trauma)	6.7	<0.001	3.1–14.9
Shark trauma (no trauma)	8.4	<0.001	3.0–23.2
Anthropogenic trauma (no trauma)	5.6	0.005	1.7–18.8
Bacterial septicemia (no septicemia)	2.9	0.003	1.5–5.8
Bacterial abscesses (no bacterial abscesses)	3.9	<0.001	1.8–8.5
Sample year 2010 (2004)	6.1	0.014	1.4–26.0

^a CI = confidence interval.

DISCUSSION

Our study has confirmed that skin wounds, but not internal mucosal lesions, are important risk factors for sea otter infection by *S. phocae*. Skin traumas due to fights, mating wounds, shark bite, boat strike, and fishing line or hook entanglement were all associated with significantly increased, but roughly equivalent, risk of *S. phocae* infection. This suggests that epithelial breaks of any kind that expose the dermis and subcutis significantly increase the risk of *S. phocae* invasion and can promote localized or systemic bacterial spread. This finding has important ramifications for managing animal transport, animal exhibits, surgery, or other activities where skin trauma could occur.

Skin trauma resulting from mating activity and fighting is common on the nose, paws, flippers, genitals, and tail of sea otters (Fig. 1A, D). These lesions are often mild but can be severe. During copulation, males grasp the female's nose with their teeth and may cause severe trauma (Staedler and Riedman 1993). Females are commonly in poor nutritional condition at the time of copulation, and animals with nose

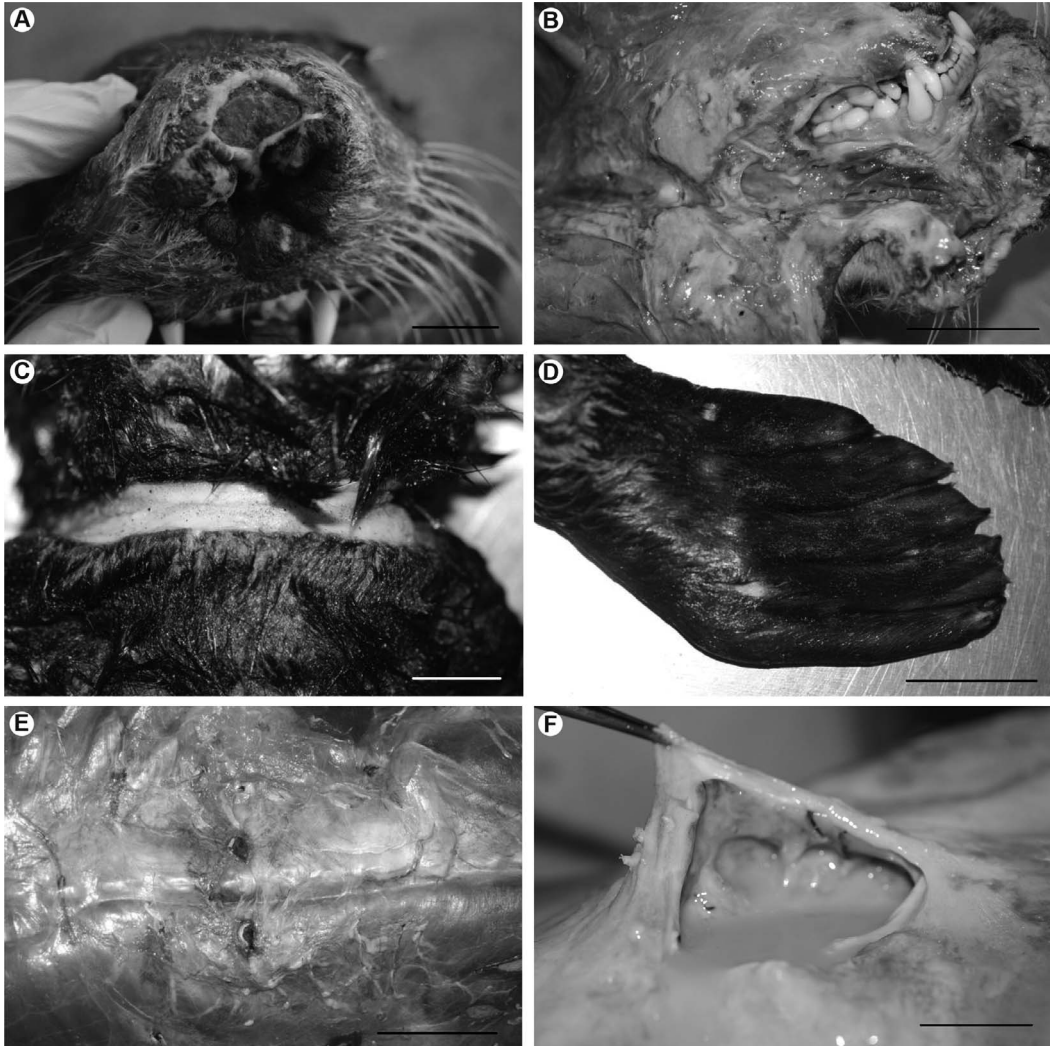


FIGURE 1. Gross lesions associated with *Streptococcus phocae* infection in necropsied southern sea otters (*Enhydra lutris nereis*) from central California, USA, 2004–2010. (A) Normal sea otter copulatory behavior results in skin wounds on the rostral face and planum nasale of females, because the male grasps this area with his teeth during mating. Occasionally, these lesions can be severe, and in this example, mating trauma has resulted in partial disruption of the planum nasale. Bar=2 cm. (B) Severe suppurative cellulitis, fasciitis, and abscessation of the subcutis of the lateral head and lower jaw of an adult female sea otter. *Streptococcus phocae* was isolated on bacterial culture, and numerous bacterial cocci were observed in affected tissues on histopathology. This demonstrates regional tissue invasion by *S. phocae* following colonization of a mating-associated nose wound. Bar=4 cm. (C) A deep skin laceration on a sea otter's neck due to chronic fishing line entanglement. Bar=2 cm. (D) Intraspecific fighting, especially between competing males, commonly results in small punctures and skin lacerations on the flippers (seen here), face, paws, and genitalia. These lesions, although comparatively mild, often become infected secondarily by *S. phocae* and other opportunistic bacterial pathogens. Bar=4 cm. (E) The two dark, linearly arranged, "stab-like" lesions on the dorsal abdominal subcutis of a sea otter are typical of a great white shark (*Carcharodon carcharias*) bite. Although southern sea otters are commonly bitten by great white sharks, these animals are rarely, if ever consumed, and death often results from secondary bacterial infection, especially *S. phocae*. Bar=3 cm. (F) A large, subacute, purulent abscess on the dorsal thoracic subcutis of a sea otter. The location of this abscess is typical of otters that survive a great white shark bite but succumb later to secondary bacterial infection, especially *S. phocae*. *Streptococcus phocae* infection was confirmed in this case via culture and histopathology. Bar=1 cm.

wounds often develop secondary bacterial infections (Fig. 1B; Kreuder et al. 2003). Anthropogenic trauma, including gunshot, fishing line entanglement, and lacerations from boat propellers can also cause skin trauma (Fig. 1C).

Great white sharks often attack southern sea otters, but rarely, if ever, consume them (Ames and Morejohn 1980), so despite significant injuries, animals often survive for days or weeks following shark attack (Fig. 1E). As a result, bacterial infection is a common cause of death following shark bite (Fig. 1F; Kreuder et al. 2003). Increased *S. phocae* detection during the final year of study could be due to enhanced case recognition, random chance, or factors that were not assessed during the study. Great white shark-associated mortality appears to be increasing in southern sea otters over time (Tinker et al. 2015) and could also lead to increased *S. phocae* infection. Studies are in progress to address this question.

Detection of abscesses or septicemia at necropsy was also predictive of *S. phocae* infection: sea otters with abscesses were nearly four times more likely, and septicemic animals three times more likely to be *S. phocae*-infected than those without either condition. Pure *S. phocae* septicemia (defined as no other bacteria isolated in culture or detected on histopathology in animals with a diagnosis of septicemia) was the primary or contributing cause of death for 10% of *S. phocae*-positive otters, suggesting that this bacterium is an important opportunistic pathogen of sea otters. As further evidence, gram-positive bacterial cocci, arranged in small groups or short chains suggestive of streptococci, are the most common bacterial morphology observed on microscopic examination of infected wounds, abscesses, and septicemic southern sea otters (M.M. unpubl. data).

Associations between skin or mucosal trauma and streptococcal infection have also been reported in fish (Gonzalez-Contreras et al. 2011) and humans (Libertin et al. 1985). In one prior report

(Libertin et al. 1985), human infection by group F streptococci rarely occurred in the absence of preexisting breaks in host defenses, with five of seven cases concurrent with gastrointestinal perforation. Similar to our findings in sea otters, abscessation and bacteremia or sepsis are relatively common sequelae following beta-hemolytic streptococcal colonization of breaks in host defenses for humans (Libertin et al. 1985).

Prior studies also provide clues regarding potential mechanisms of *S. phocae* attachment, invasion, and systemic spread. In fish, *S. phocae* utilizes hydrophobic interactions to assist with nonspecific adhesion to the epithelium (Doyle 2000). These bacteria cannot invade an intact epidermis and instead survive at the surface, feeding on mucus. However, epidermal breaks and the disruption of mucosal defenses appear to facilitate *S. phocae* invasion in fish (Gonzalez-Contreras et al. 2011). A recent study of alpha-hemolytic *Streptococcus infantarius* subspecies *coli* isolates derived from sea otters with bacterial endocarditis revealed that all strains adhered significantly to exposed extracellular matrix components in vitro, including collagen IV, fibronectin, laminin, and hyaluronic acid (Edgar 2010). Bacterial survival was also documented following phagocytosis by macrophages. These same mechanisms could be used by the related bacterium, *S. phocae*, to attach to exposed extracellular matrix and spread systemically.

Potential environmental sources of *S. phocae* exposure include the marine environment and seawater (Kusuda and Kawai 1982; Interaminense et al. 2010), endogenous oral-fecal flora of sea otters and other animals (Johnson et al. 2006; Imai et al. 2009; Miller et al. 2010), and traumatic inoculation, with studies of bacterial flora from the teeth and oral cavities of great white (Buck et al. 1984), tiger (*Galeocerdo cuvier*), and bull sharks (*Carcharhinus leucas*; Interaminense et al. 2010) confirming that streptococci could be inoculated into wounds during a shark attack. However, our data suggest that the risk of *S. phocae*

infection in sea otters is not associated with any single source of trauma but instead is associated with skin lesions of any type. This information, combined with culture data suggesting that *S. phocae* is not a common commensal bacterium of live wild, apparently healthy, southern sea otters (M.M. unpubl. data), and reports of fatal *S. phocae* infections of marine animals worldwide (Skaar et al. 1994; Henton et al. 1999; Vossen et al. 2004; Imai et al. 2009; Hueffer et al. 2011) suggest that *S. phocae* is ubiquitous in the marine environment, and infection is associated with opportunistic colonization of damaged skin.

Studies of streptococcal infections in farmed fish also support the concept of marine environmental exposure. Streptococci can survive up to 42 d in marine water with salinity from 0 to 7‰, and pH ranges from 3.5 to 10. Bacterial proliferation can occur in the water column and in benthic mud at water temperatures from 10 to 45 °C (Kusuda and Kawai 1982). Human beta-hemolytic streptococcal infections are also often associated with “wounds received in the marine environment” (Interaminense et al. 2010).

It is common for fishermen, divers, marine mammal care workers, and aquarium staff to develop bacterial skin infections after working in marine environments, including handling live or dead animals, especially if there are preexisting skin breaks. The associated infectious cellulitis, often called “seal finger,” is commonly attributed to infection by *Mycoplasma phocacerebrale*, *atypical mycobacteria*, *Vibrio vulnificus*, *other Vibrio spp.*, or *Erysipelothrix rhusiopathiae* (White and Jewer 2009). Based on their high prevalence of infection in marine animals and fish, their global distribution and propensity for colonizing skin breaks, it is possible that some cases of seal finger in humans are unrecognized infections by *S. phocae* or other beta-hemolytic streptococci.

Our findings confirm that skin wounds and associated abscesses are a common portal of invasion and systemic spread by *S. phocae* and other beta-hemolytic

streptococci in sea otters. These findings benefit sea otter care and management by highlighting the importance of these infections, facilitating case recognition and guiding antibiotic selection. Significant associations between skin trauma and fatal *S. phocae* infection in necropsied sea otters also suggest that efforts to minimize trauma during capture activities, transport, washing of oiled animals, and captive care are advisable. Because exposed dermis and subcutis appear to facilitate streptococcal invasion and spread, careful closure of wounds and surgical sites can also help minimize risk. Finally, studies of the potential for *S. phocae* and other beta-hemolytic streptococci to infect humans may reveal that these bacteria are more common human pathogens than is currently recognized.

ACKNOWLEDGMENTS

We thank staff at the University of Liverpool, National Centre for Zoonosis Research for their support. We thank Sara Miller for her assistance with preparation of the figures. We also thank the staff at California Department of Fish and Wildlife—Marine Wildlife Veterinary Care and Research Center for their assistance with project completion, along with all organizations and individuals that have submitted stranded southern sea otters for postmortem examination. G.B. thanks Alicia Coupe for her relentless support and the Wellcome Trust for support that facilitated travel abroad to complete this study.

LITERATURE CITED

- Ames JA, Morejohn GV. 1980. Evidence of white shark, *Carcharodon carcharias*, attacks on sea otters, *Enhydra lutris*. *Calif Fish Game* 66:196–209.
- Bishop EJ, Shilton C, Benedict S, Kong F, Gilbert GL, Gal D, Godoy D, Spratt BG, Currie BJ. 2007. Necrotizing fasciitis in captive juvenile *Crocodylus porosus* caused by *Streptococcus agalactiae*: An outbreak and review of the animal and human literature. *Epidemiol Infect* 135:1248–1255.
- Buck JD, Spotte S, Gadbaw JJ Jr. 1984. Bacteriology of the teeth from a great white shark: Potential medical implications for shark bite victims. *J Clin Microbiol* 20:849–851.
- Burek KA, Gill VA, Doroff AM, Tuomi P, Goldstein T, Miller MA, Jang SS, Shewmaker L, Bodkin

- JL. 2005. Valvular endocarditis and septicemia due to *Streptococcus infantarius* ssp. *coli* organisms in stranded northern (*Enhydra lutris kenyoni*) and southern sea otters (*Enhydra lutris nereis*). In: *Proceedings of the international association for aquatic animal medicine 36th annual conference*, XXXXX XXXX, Seward, Alaska, 14–18 May, pp. 215–217.
- Counihan-Edgar K, Gill V, Doroff A, Burek K, Miller W, Shewmaker P, Jang S, Goertz C, Tuomi P, Miller M, et al. 2012. Genotypic characterization of *Streptococcus infantarius* subsp. *coli* isolates from sea otters with infective endocarditis and/or septicemia and from environmental mussel samples. *J Clin Microbiol* 50:4131–4133.
- Doyle RJ. 2000. Contribution of the hydrophobic effect to microbial infection. *Microbes Infect* 2:391–400.
- Edgar KL. 2010. *Pathogenesis of Streptococcus infantarius subspecies coli valvular endocarditis in sea otters*. PhD Dissertation, University of California, Davis, Davis, California, 96 pp.
- Fischer A, Liljander A, Kasper H, Muriuki C, Fuxelius HH, Bongcam-Rudloff E, de Villiers EP, Huber CA, Frey J, Daubenberger C, et al. 2013. Camel *Streptococcus agalactiae* populations are associated with specific disease complexes and acquired the tetracycline resistance gene *tetM* via a Tn916-like element. *Vet Res* 44:86.
- Gonzales-Contreras A, Magarinos B, Godoy M, Irgang R, Toranzo AE, Avendano-Herrera R. 2011. Surface properties of *Streptococcus phocae* strains isolated from diseased Atlantic salmon, *Salmo salar* L. *J Fish Dis* 34:203–215.
- Henton MM, Zapke O, Basson PA. 1999. *Streptococcus phocae* infections associated with starvation in Cape fur seals. *J S Afr Vet Assoc* 70:98–99.
- Hueffer K, Lieske CL, Mcgilvary LM, Hare RF, Miller DL, O'Hara TM. 2011. *Streptococcus phocae* isolated from a spotted seal (*Phoca largha*) with pyometra in Alaska. *J Zoo Wildl Med* 42:108–112.
- Imai D, Jang SS, Miller MA, Conrad PA. 2009. Characterization of beta-hemolytic streptococci isolated from southern sea otters (*Enhydra lutris nereis*) stranded along the California coast. *Vet Microbiol* 136:378–381.
- Interaminense JA, Nascimento DCO, Ventura RF, Batista JEC, Souza MMC, Hazin FHV, Pontes-Filho NT, Lima-Filho JV. 2010. Recovery and screening for antibiotic susceptibility of potential bacterial pathogens from the oral cavity of shark species involved in attacks on humans in Recife, Brazil. *J Med Microbiol* 59:941–947.
- Johnson S, Lowenstein L, Gulland F, Jang S, Imai D, Almy F, Delong R, Gardner I. 2006. Aerobic bacterial flora of the vagina and prepuce of California sea lions (*Zalophus californianus*) and investigation of associations with urogenital carcinoma. *Vet Microbiol* 114:94–103.
- Keefe GP. 1997. *Streptococcus agalactiae* mastitis: A review. *Can Vet J* 38:429–437.
- Kreuder C, Miller MA, Jessup DA, Lowenstein LJ, Harris MD, Ames JA, Carpenter TE, Conrad PA, Mazet JAK. 2003. Patterns of mortality in southern sea otters (*Enhydra lutris nereis*) from 1998–2001. *J Wildl Dis* 39:495–509.
- Kusuda R, Kawai K. 1982. Characteristics of *Streptococcus* sp. pathogenic to yellowtail. *Fish Pathol* 17:11–16.
- Lamm CG, Ferguson AC, Lehenbauer TW, Love BC. 2010. Streptococcal infection in dogs: A retrospective study of 393 cases. *Vet Pathol* 47:387.
- Libertin CR, Hermans PE, Washington JA. 1985. Beta-hemolytic group F streptococcal bacteremia: A study and review of the literature. *Rev Infect Dis* 7:498–503.
- Miller MA, Byrne BA, Yang SS, Dodd EM, Dorfmeier E, Harris MD, Ames JA, Paradies D, Worcester K, Jessup DA, et al. 2010. Enteric bacterial pathogen detection in southern sea otters (*Enhydra lutris nereis*) is associated with coastal urbanization and freshwater runoff. *Vet Res* 41:1–12.
- Romalde JL, Ravelo C, Valdes I, Magarinos B, Del La Fuente E, San Martin C, Avendano-Herrera R, Toranzo AE. 2008. *Streptococcus phocae*, an emerging pathogen for Salmonid culture. *Vet Microbiol* 130:198–207.
- Skaar I, Gaustad P, Tonjum T, Holm B, Stenwig H. 1994. *Streptococcus phocae* sp. nov., a new species isolated from clinical specimens from seals. *Int J Syst Bacteriol* 44:646–650.
- Staedler M, Riedman M. 1993. Fatal mating injuries in female sea otters (*Enhydra lutris nereis*). *Mammalia* 57:135–139.
- Tillman PC, Dodson ND, Indiveri M. 1982. Group G streptococcal epizootic in a closed cat colony. *J Clin Microbiol* 16:1057–1060.
- Tinker, T, Hatfield, B, Harris M, Ames J. 2015. Dramatic increase in sea otter mortality from white sharks in California. *Marine Mammal Science* doi: 10.1111/mms.12261.
- Vossen A, Abdulmawjood A, Lämmler C, Weiß R, Siebert U. 2004. Identification and molecular characterization of beta-hemolytic streptococci isolated from harbor seals (*Phoca vitulina*) and grey seals (*Halichoerus grypus*) of the German North and Baltic seas. *J Clin Microbiol* 42:469–473.
- White CP, Jewer DD. 2009. Seal finger: A case report and review of the literature. *Can J Plast Surg* 17:133–135.

Submitted for publication 20 February 2015.

Accepted 5 June 2015.