

Word count: 2952

## **Abstract**

**Objective** To evaluate the incidence of corneal abrasions/ulceration and microbial contamination in horses undergoing general anaesthesia.

**Study design** Prospective, observational, clinical study.

**Animals** A total of 40 client-owned healthy horses scheduled for elective non-ophthalmic procedures.

**Methods** Conjunctival sac swabs were taken, fluorescein dye applied and digital images recorded from both eyes of the horses after pre-anaesthetic medication and 24 hours after recovery from general anaesthesia. A paraffin-based bland ophthalmic ointment was applied on the ocular surface intra-operatively following collection of a sample into a sterile container. All samples underwent aerobic, anaerobic and fungal culture. Subject demographics, chronology of ophthalmic ointment use, anaesthesia duration, recumbency after induction, during surgery and recovery, fluorescein uptake and culture results were recorded. Descriptive statistics were performed.

**Results** Complete data were collected from thirty-four horses; six (17.6 %) developed mild unilateral generalized fluorescein uptake consistent with corneal abrasions. Recumbency on the operating table was the only risk factor significantly associated with corneal abrasions. A total of 11 bacterial species were identified; *Staphylococcus* spp. (15 eyes) and *Micrococcus* spp. (8 eyes) were the most frequently isolated bacteria. Two fungal species were isolated postoperatively (*Aspergillus* spp., *Saccharomyces* spp.) in 2 eyes. Ointment contamination was recorded in two cases (5%) but cross-contamination was not recognized.

**Conclusions and clinical relevance** Incidence of corneal abrasion/ulceration in horses undergoing general anaesthesia and contamination rate of ophthalmic solutions is similar to that previously reported in dogs.

**Keywords** Anaesthesia, morbidity, horses, corneal abrasion, risk factors, topical lubrication

## **Introduction**

Corneal abrasion is the most common ophthalmic complication in people undergoing general anaesthesia for non-ocular surgery (Grixti & Watts 2013). Incidence varies between 0.056% (Roth et al. 1996) and 44% (Batra & Bali 1997) depending on surgical population, prophylactic measures employed and method of assessment (Grixti & Watts 2013). In dogs the incidence of anaesthesia associated iatrogenic corneal disease is reported as varying between 1.9 % (Park et al. 2013) and 19.1% (Dawson & Sanchez 2016) depending on severity of lesion considered. General anaesthesia obtunds or abolishes the protective palpebral reflex, causes lagophthalmos and decreases tear production in both human (Moos & Lind 2006) and equine (Brightman et al. 1983). The resulting degradation of the precorneal tear film, coupled with the risks of mechanical trauma from surgical drapes or instruments, chemical trauma from contact with skin preparation solutions or direct irritant effect of inhalant anaesthetics can result in corneal insult (White & Crosse 1998). Horses have laterally situated, prominent eyes, which, coupled to the factors mentioned above, may make them susceptible to suffering corneal damage as a result of undergoing general anaesthesia.

In human medicine, various methods of protecting the ocular surface during general anaesthesia have been recommended, including eyelid taping, insertion of hydrophilic contact lenses and instillation of paraffin-based ointments, aqueous solutions or viscous gels onto the corneal surface. None of these methods however has been recognised as completely effective and free of potential adverse effects (White & Crosse 1998; Kocaturk et al. 2012). In veterinary medicine, corneal application of a bland ophthalmic

ointment, usually supplied in a multiuse container, is commonly employed, however microbial contamination of multiple application containers is well-recognized in human medicine and has been associated with corneal infections and perforations (Rahman et al. 2006, Kim et al. 2008). To the authors' knowledge the incidence of anaesthesia associated corneal damage or efficacy of ocular protection strategies have not been reported in horses.

The primary aim of our study was to evaluate the incidence and potential risk factors for corneal abrasion in systemically healthy horses undergoing general anaesthesia for elective surgical procedures and administered a bland, paraffin-based ophthalmic ointment for corneal protection. We also sought to ascertain whether microbial contamination of the ophthalmic ointment occurred and whether this had an impact on the naturally occurring ocular micro-flora of these horses.

We hypothesized that the incidence of corneal abrasion would be similar to or greater than previously reported in humans and dogs and that microbial contamination of the ointment would occur leading to cross-contamination.

## **Material and methods**

The study received ethical approval from the Veterinary Research Ethics Committee of the University of Liverpool (VREC342) and informed owner consent was obtained for all animals. Horses were deemed eligible for inclusion in the study if systemically healthy, older than one year of age, undergoing inhalational general anaesthesia for elective non-ocular procedures, without history of ocular disease and not on any antimicrobial treatment. Following administration of pre-anaesthetic medication, samples were taken from the conjunctival sac of both eyes using a dry cotton swab and placed in Amies transport media with charcoal (Deltalab, Spain). Care was taken to avoid contacting the

eyelid, vibrissae, eyelashes and corneal surface with the swab. Immediately after, fluorescein dye (Fluorescein Sodium 1%; Bausch & Lomb, UK) was applied on the corneal surface, the presence of abrasions/ulceration was visually evaluated and digital images were recorded for both eyes. General anaesthesia was induced and once the horse was positioned on the operating table, a preservative free, paraffin based bland ophthalmic ointment (Lacri-Lube; Allergan, Ireland) was applied to the ocular surface, as is routinely performed at this institution, after first collecting an approximately 2cm length of sample into a sterile container. Care was taken not to touch the cornea to avoid direct mechanical trauma by the applicator tip. Ointment was not reapplied during the procedure. Anaesthetic protocol was at the discretion of the anaesthetist and prophylactic antimicrobial treatment at the discretion of the surgeon responsible for the case. Conjunctival swabs, fluorescein staining and digital imaging were repeated 24 hours after the horses regained standing following anaesthesia. All procedures for data collection were performed by DB or SS and all digital images were reviewed at the end of data collection, by SS.

Samples were either transported to the laboratory immediately or stored at 4 °C for no more than 24 hours. All analyses were performed by the microbiology laboratory of the University of Liverpool. Bacterial culture was performed on 5% sheep blood agar (Thermo Scientific, UK) incubated aerobically and anaerobically for up to 7 days at 37°C. Sabouraud dextrose agar with chloramphenicol (Thermo Scientific, UK) was used for fungal culture with incubation at 37°C for 7-10 days (yeast and fungi). Bacterial cultures were identified using a biochemical identification kit (API; Biomerieux, France).

Demographic data, type and length of procedure, length of recovery, recumbencies (at induction, intraoperatively and in recovery), details of ointment used (tube number,

duration of use and number of horses on which it has been used), incidence of corneal abrasions or ulcers and culture results were recorded.

Corneal abrasion was defined as a mild and generalized fluorescein uptake, whereas corneal ulceration was defined as an obvious, strong and well demarcated region of uptake of fluorescein stain (Dawson & Sanchez 2016).

Horses that developed corneal abrasions or ulceration were monitored and treated as appropriate.

### **Statistical analysis**

Statistical analysis was performed using the statistical software IBM SPSS Statistic 24. Sample size calculation to detect an incidence of corneal damage of 30% (an arbitrarily assigned value, representing an incidence midway between the maxima previously reported in dogs and humans), with a power of 0.8 and the alpha level set at 0.05 indicated that 42 horses were required. Distribution of data was assessed visually and using a Shapiro-Wilk test. Normally distributed data are reported as mean  $\pm$  standard deviation (SD). Differences between groups were compared with two-sample t-test. Non-normally distributed data are reported as median (range). Differences between groups were compared with Mann-Whitney U test. Binomial logistic regression was used to investigate the effects of weight, age, sex, anaesthesia and recovery duration, and recumbency at induction, intraoperatively and in recovery, on outcome of corneal lesions. A value of  $p < 0.05$  was considered statistically significant.

### **Results**

A total of 40 horses were recruited to the study. Six were subsequently excluded; one was euthanized in recovery because of severe myopathy and five were discharged from the

hospital within 24 hours from recovery time, precluding collection of postoperative samples. Statistical analysis was therefore performed on 34 horses.

No horses developed corneal ulceration. Six of 34 (17.6%) developed corneal abrasions (Fig. 1). Horses which developed corneal abrasions did not differ from those without corneal abrasions with respect to age, weight, sex, breed or length of recovery. Duration of anaesthesia and total length of recumbency were significantly longer in horses which developed corneal abrasions than in those which did not (Table 1).

When association between recumbency at induction, on the operating table and in recovery, and development of corneal abrasions was investigated, a significance was found for intraoperative position ( $p = 0.01$ ) whereas recumbency at induction ( $p = 0.52$ ) and in recovery ( $p = 0.72$ ) were not significantly different between the two groups (Table 1).

Binomial logistic regression (Table 2) indicated that recumbency on the operating table was the only risk factor significantly associated with corneal abrasions. Dorsal recumbency decreased the risk of abrasions by 99.2% to 61.0% when compared to lateral recumbency ( $p = 0.008$ ). Four (66%) horses that developed corneal abrasions were in lateral recumbency on the operating table; in three cases the non-dependent eye and one case the dependent eye was involved.

A rope recovery system was introduced in the hospital during the study period. Twenty two horses had non-interventional recoveries and three (13.6%) developed corneal abrasions. Twelve horses had interventional recoveries and three (25%) developed corneal abrasions.

In all cases, horses which developed corneal abrasions were clinically asymptomatic, these only being detected following fluorescein staining. All cases resolved within 24

hours with supportive treatment. Overall, positive bacterial cultures were obtained from 22 (64.7%) horses; 85.5% of isolates were Gram positive whereas 15.5% were Gram negative bacteria; six (27.3%) horses had positive bacterial cultures only preoperatively, seven (31.8%) had positive bacterial cultures only postoperatively and nine (40.9%) had positive bacterial cultures both pre- and postoperatively. Nine identifiable genera and two unidentified Gram-negative bacteria were cultured (Table 3). Three (13.7%) and five (22.7%) horses had more than one bacterial species isolated pre- and post-operatively respectively. Total number of isolates was 23 pre- and 22 postoperatively. Preoperatively, 82.6% of isolates were gram-positive, with *Staphylococcus* spp. being the most frequently isolated bacteria (52.2%), followed by *Corynebacterium* spp. (17.4%). Gram-negative bacteria were isolated in four cases.

Gram-positive isolates were also the predominant bacterial organism isolated postoperatively (86.4%) with *Staphylococcus* spp. being the most frequently isolated bacteria (45.5%), followed by *Micrococcus* spp. (27.3%). Gram-negative bacteria were isolated in three cases.

Two genera of fungi were isolated from two horses, in both cases postoperatively; *Saccharomyces* spp. and *Aspergillus* spp.

The median duration of use of ointment tubes was 15 (0–78) days. Bacterial contamination of ophthalmic ointment was identified on two occasions (5.8%), both relating to the same tube; in one case *Staphylococcus aureus* and in the other *Staphylococcus* coagulase negative were isolated. These instances were not consecutive; the first isolation occurred six days after the tube had been opened and had been applied to one horse previously, the second occurred 21 days later following application to a further two horses. In six cases the ointment tube had been opened for more than 30 days and none of these produced a positive culture. There was no evidence of ointment acting

as a vehicle for cross contamination between horses and none of the horses on which that ointment was used developed corneal lesions.

## **Discussion**

None of the horses included in this study developed corneal ulcers and the incidence of corneal abrasions was 17.6%, despite application of a prophylactic topical ointment. An association between length of anaesthesia and recumbency on the operating table and development of corneal abrasions was found, but when logistic regression was performed, only lateral position on the operating table was recognized as risk factor. The incidence of bacterial contamination of the ophthalmic ointment was low (5.8%) and no cross contamination between horses was found.

Independent risk factors associated with increased incidence of corneal abrasion in humans are duration of anaesthesia, lateral or prone position, elective *versus* emergency procedures, surgery on the head or the neck, sustained intraoperative hypotension and preoperative anaemia (Roth et al. 1996). Length of anaesthesia and type of procedure have been recognized as risk factors for development of corneal ulcers also in dogs, together with skull conformation and application of fentanyl patches (Park et al. 2013).

The incidence of corneal abrasions found in this study is similar to that previously reported in dogs undergoing general anaesthesia under the protection of a topical gel protocol (Dawson & Sanchez 2016). These findings suggest that, as in human medicine, the application of a prophylactic eye ointment is not completely effective. Considering the multifactorial aetiology for corneal lesions in patients undergoing general anaesthesia, this is not unexpected. Whilst application of a topical ointment may reduce or prevent lesions resulting from corneal drying, it is unlikely to provide an effective barrier to mechanical trauma and others protective methods should be investigated. Horses may be particularly susceptible to mechanical corneal trauma due to the position and prominence



of their eyes, particularly during the anaesthetic induction and recovery periods, when direct corneal contact with the floor and walls of the recovery box cannot be prevented.

Lateral positioning has been identified as a risk factor for corneal abrasions in human studies (Roth et al. 1996, Yu et al. 2010), but not in dogs (Dawson & Sanchez 2016).

There appears to be no evidence that either the dependent or non-dependent eye is at any greater risk of injury. Roth et al (1996) identified corneal abrasion development in six patients, 3 cases involved the non-dependent eye, 2 cases the dependent eye and 1 case both eyes. Yu et al (2010) reported eye injury in two patients in lateral recumbency; in both cases both eyes were involved. In our study, four (66%) horses that developed corneal abrasions were in lateral recumbency on the operating table; three cases involved the non-dependent eye and one case the dependent eye. Due to the small number of cases, statistical analysis to find a relationship between affected eye and positioning was not performed but a similarity with human literature can be suspected.

In our study, ointment was applied only at the beginning of the procedure, regardless of the duration of anaesthesia. In human medicine there is no standardized protocol for the timing of ointment application, but other adjunctive strategies, such as eyelid taping, are often used. Neither of the studies performed in dogs, (where the only protective strategy was ophthalmic lubricant) identified the timing of ointment application as influencing the occurrence of corneal abrasions.

Duration of anaesthesia has been recognized as an independent risk factor for the development of corneal injuries both in humans (Roth et al. 1996; Martin et al 2009) and in dogs (Park et al. 2013); in our study, despite the length of anaesthesia in horses with corneal abrasions being significantly longer than in horses without abrasions, logistic regression failed to identify duration of anaesthesia as a risk factor. This result could be explained by the small number of animals included in the study.

A confounding effect between duration of anaesthesia, recumbency on the operating table and type of procedure cannot be excluded; multivariate analysis was not performed because of the limited number of animals included in the study.

The overall incidence of positive bacterial cultures in our study was 64.7% and the vast majority (84.5%) of isolates were gram positive bacteria. *Staphylococcus* spp., *Micrococcus* spp. and *Corynebacterium* spp. were the most frequently represented. This is in agreement with Johns et al. (2011) who reported a similar incidence (52%), with the same gram positive bacteria being isolated from healthy UK horses. The prevalence of gram negative bacteria (48%) and fungi (13%) reported by these authors was higher compared with our results. Season (Whitley et al. 1983), housing (Moore et al. 1988, Barsotti et al. 2006) and age (Andrew et al. 2003) have all been reported to affect frequency and composition of bacterial and fungal flora in horses and these factors could easily explain this discrepancy. Gram positive bacteria, particularly *Staphylococcus* spp., *Streptococcus* spp, *Corynebacterium* spp and less commonly *Bacillus* spp, predominate in the normal ocular surface microflora but can become pathogenic in the presence of ocular surface disease, leading to keratitis or infected corneal ulcers (Ferreira et al. 2017). Knowledge of the normal or opportunistic ocular microflora of healthy horses is therefore useful in directing empiric therapy in case of corneal lesions before culture and sensitivity testing is available. The low frequency of ophthalmic ointment contamination and absence of cross contamination was an unexpected result. Certain types of drugs (prednisolone, acetylcysteine and hypromellose) and preservative-free preparations are at increased risk of bacterial contamination (Rahaman et al. 2006). Inclusion of a preservative in eye lubricants has however been associated with severe chemical corneal epithelial injuries in people, therefore preservative free preparations are recommended (Grixti et al 2013).

Correlation between incidence of contamination and length of time the container has been used has been investigated in several studies in human medicine leading to conflicting results. Fazeli et al. (2004) reported an increased risk of contamination after 7 days of use whereas Livingstone et al. (1998) reported no increased incidence of contamination at 14 days of use. Betbeze et al (2007) investigated the incidence of bacterial contamination of multidose ophthalmic solutions in the ophthalmology service of a small animal veterinary teaching hospital and found no clinically significant bacterial contamination in any of the samples examined. These authors concluded that, if stored and administered according to manufacturer's' recommendations, these bottles can be used safely for up to two weeks.

The manufacturer of the ophthalmic ointment used in this study advises discarding the tube one month after opening. It is routine practice in our hospital to use it until empty. Overall, the tubes had been used for a median time of 15 (0 – 78) days; in six cases the tube had been opened for more than 30 days and none of these produced a positive culture. However, one limitation of the study is that ointment storage conditions were different from routine. Ointment tubes used for the study were kept separately and not in the operating theatre, as usually performed at our institution, and this could have resulted in a lesser degree of contamination.

The main limitation is the power of the study. A post-hoc power calculation performed using our identified incidence of abrasions of 17% indicated a power of 58.5%. To achieve our intended power of 80% with this incidence, 82 horses would need to be included in a future study.

All but one horse received preoperative prophylactic antimicrobial treatment on the day of the procedure. This consisted of intramuscular procaine penicillin which was administered between 5 minutes and 4 hours prior to acquiring the preoperative samples. It is possible that this could have influenced the microbial culture results we obtained.

However, Punch et al. (1985) reported that in cattle, after intramuscular administration, penicillin was detectable in tears in only 2 of 204 tear samples investigated over a 24-hour period. In both these cases the antimicrobial concentration was lower than the Minimum Inhibitory Concentration for *Moraxella bovis*. To the authors' knowledge there are no similar studies in horses, but 22 isolates were cultured from 16 horses postoperatively, showing a similar micro-flora to that obtained pre-operatively. We therefore think it unlikely the antimicrobial treatment significantly altered the microflora over the study period.

During the study, a rope recovery system was introduced at our institution and this may have influenced the development of corneal abrasions. Due to the small number of animals involved however it was not possible to draw any significant conclusion. Recovery is the most risky phase in equine anaesthesia and the ideal recovery system has not yet been determined. Further studies are warranted to investigate any possible correlation between type of recovery system and incidence of corneal abrasions.

In conclusion, horses undergoing general anaesthesia for elective procedures developed corneal abrasions despite the application of ocular lubricant. Awareness of clinically asymptomatic iatrogenic perioperative corneal injury should encourage implementation and evaluation of preventive strategies (Martin et al. 2009) and the possible association between length of anaesthesia and recumbency on the operating table and incidence of corneal abrasion should be further investigated.

## References

295 Andrew SE, Nguyen A, Jones GL, Brooks DE (2003) Seasonal effects on the aerobic  
296 bacterial and fungal conjunctival flora of ormal thoroughbred brood mares in Florida. *Vet*  
297 *Ophthalmol* 6, 45-50.

298 Barsotti G, Sgorbini M, Nardoni S et al. (2006) Occurrence of fungi from conjunctiva of  
299 healthy horses in Tuscany, Italy. *Vet Res Commun* 30, 903-906.

300 Batra YK, Bali IM (1997) Corneal abrasions during general anesthesia. *Anesth Analg* 56,  
301 363-365.

302 Betbeze CM, Stiles J, Krohne SG (2007) Assessment of bacterial contamination of three  
303 multidose ophthalmic solutions. *Vet Ophthalmol* 10, 81-83.

304 Brightman AH, Manning JP, Benson GJ et al (1983) Decreased tear production associated  
305 with general anaesthesia in the horse. *J Am Vet Med Assoc* 182, 182-243.

306 Dawson C, Sanchez, RF (2016) A prospective study of the prevalence of corneal surface  
307 disease in dogs receiving prophylactic topical lubrication under general anesthesia. *Vet*  
308 *Ophthalmol* 19, 124-129.

309 Fazeli MR, Nejad HB, Mehrgan H, Elahian L (2004) Microbial contamination of  
310 preserved ophthalmic drops in outpatient departments: possibility of an extended period  
311 of use. *Daru* 12, 151- 155.

312 Ferreira ARA, Santana AF, da Veiga Rodarte de Almeida AC et al (2017) Bacterial  
313 culture and antibiotic sensitivity from the ocular conjunctiva of horses. *Ciência*  
314 *Rural*, 47(6), e20160753. Epub May 22, 2017.[https://dx.doi.org/10.1590/0103-](https://dx.doi.org/10.1590/0103-8478cr20160753)  
315 [8478cr20160753](https://dx.doi.org/10.1590/0103-8478cr20160753)

316 Grixti A, Watts MT (2013) Corneal protection during general anesthesia for nonocular  
317 surgery. *Ocul Surf* 11, 109-118.

318 Johns IC, Baxter K, Booler H et al (2011) Conjunctival bacterial and fungal flora in  
319 healthy horses in UK. *Vet Ophthalmol* 14, 195-199.

320 Kim MS, Choi CY, Kim JM et al. (2008) Microbial contamination of multiply used  
321 preservative-free artificial tears packed in reclosable containers. *Br J Ophthalmol* 92,  
322 1518-1521.

323 Kocaturk O, Kocaturk T, Kaan N et al. (2012) The comparison of four different methods  
324 of perioperative eye protection under general anaesthesia in prone position. *J Clin Anal*  
325 *Med* 3, 163-165.

326 Livingstone DJ, Hanlon GW and Dyke S (1998) Evaluation of an extended period of use  
327 for preserved eye drops in hospital practice. *Br J Ophthalmol* 82, 473-475.

328 Martin DP, Weingarten TN, Gunn PW et al. (2009) Performance improvement system  
329 and postoperative corneal injuries. *Anesthesiology* 111, 320-326.

330 Moore CP, Heller N, Majors LJ et al. (1988) Prevalence of ocular microorganisms in  
331 hospitalised and stabled horses. *Am J Vet Res* 49, 773-779.

332 Moos DD, Lind DM (2006) Detection and treatment of perioperative corneal abrasions.  
333 *J Perianesth Nurs* 21, 332-338.

334 Park YW, Son WG, Jeong MB et al. (2013) Evaluation of risk factors for development of  
335 corneal ulcer after nonocular surgery in dogs: 14 cases. *J Am Vet Med Assoc* 24, 1544-  
336 1548.

337 Punch PI, Costa ND, Chambers ED et al. (1985) Plasma and tear concentrations of  
338 antibiotic administered parenterally to cattle. *Res Vet Sci* 39, 179-187.

339 Rahman MQ, Tejwani D, Wilson JA et al. (2006) Microbial contamination of  
340 preservative free eye drops in multiple application containers. Br J Ophthalmol 90, 139-  
341 141.

342 Roth S, Thisted RA, Erickson JP et al. (1996) Eye injuries after nonocular surgery. A  
343 study of 60,965 anesthetics from 1988 to 1992. Anesthesiology 85, 1020-1027.

344 White E, Crosse MM (1998) The aetiology and prevention of peri-operative corneal  
345 abrasions. Anaesthesia 53, 157-161.

346 Whitley RD, Burgess EC, Moore CP (1983) Microbial isolates of the normal equine eye.  
347 Equine Vet J suppl. 2, 138-140.

348 Yu HD, Chou AH, Yang MW, Chang CJ (2010) An analysis of perioperative eye injuries  
349 after nonocular surgery. Acta Anaesthesiol Taiwan 48, 122-129.

350

**Table 1** Comparative data for horses undergoing elective general anaesthesia which did (Group CA) or did not (Group NCA) develop corneal abrasions. Data are presented as mean  $\pm$  standard deviation or median (minimum-maximum). M, male; F, female; RL, right lateral; LL, left lateral; D, dorsal.  $p < 0.05$  = significant.

| Variable                             | Group NCA            | Group CA            | <i>p</i> -value |
|--------------------------------------|----------------------|---------------------|-----------------|
| Age (years)                          | 10 $\pm$ 5           | 11 $\pm$ 7          | 0.357           |
| Weight (Kg)                          | 611<br>(106-750)     | 596<br>(498-670)    | 0.77358         |
| Gender                               | 25 M<br>3 F          | 4 M<br>2 F          | 0.399           |
| Anaesthesia length<br>(minutes)      | 110 $\pm$ 34         | 139 $\pm$ 15        | 0.027360361     |
| Recovery length<br>(minutes)         | 28<br>(13-85)        | 36<br>(21-70)       | 0.22362         |
| Total recumbency length<br>(minutes) | 145 $\pm$ 45         | 181 $\pm$ 20        | 0.04363         |
| Recumbency at induction              | 18 RL<br>10 LL       | 3 RL<br>3 LL        | 0.324           |
| Recumbency on the table              | 25 D<br>1 RL<br>2 LL | 2 D<br>1 LL<br>3 RL | 0.01365366      |
| Recumbency in recovery               | 19 RL<br>9 LL        | 3 RL<br>3 LL        | 0.72367         |



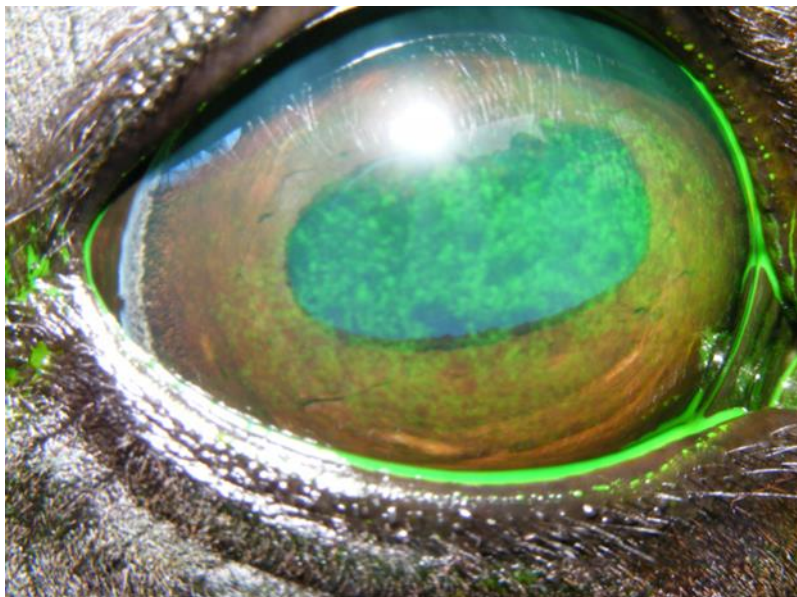
**Table 2** Binomial logistic regression evaluating potential risk factors for development of corneal abrasions in horses undergoing general anaesthesia for elective procedures. OR, odd ratio; CI, Confidence Intervals; RL, right lateral; LL, left lateral; D, dorsal; L, lateral

|                                 | OR   | CI (95%)  | <i>p</i> value       |
|---------------------------------|------|-----------|----------------------|
| Weight                          | 1.00 | 0.99-1.01 | 0.82 <sup>375</sup>  |
| Age                             | 1.06 | 0.89-1.27 | 0.52 <sup>376</sup>  |
| Gender                          | 0.24 | 0.03-1.92 | 0.18 <sup>377</sup>  |
| Anaesthesia length              | 1.04 | 0.1- 1.08 | 0.06 <sup>378</sup>  |
| Recovery length                 | 1.02 | 0.98-1.07 | 0.34                 |
| Recumbency induction (RL vs LL) | 0.55 | 0.09-3.28 | 0.52 <sup>379</sup>  |
| Recumbency table (D vs L)       | 0.06 | 0.01-0.45 | 0.008 <sup>380</sup> |
| Recumbency recovery (RL vs LL)  | 0.47 | 0.08-2.83 | 0.41 <sup>381</sup>  |

**Table 3** Microflora cultured from pre- and post-operative conjunctival swabs in horses undergoing general anaesthesia. Results are presented as frequency of isolates (percentage of total isolates).

| Bacteria                             | Pre-operative sample | Post-operative sample |
|--------------------------------------|----------------------|-----------------------|
| <b>Gram-positive</b>                 |                      |                       |
| <i>Staphylococcus</i> spp.           | 12 (52.2%)           | 10 (45.5%)            |
| <i>Corynebacterium</i> spp.          | 4 (17.4%)            | 0                     |
| <i>Micrococcus</i> spp.              | 1 (4.3%)             | 6 (27.3%)             |
| <i>Bacillus</i> spp.                 | 1 (4.3%)             | 1 (4.5%)              |
| <i>Kocuria rosea</i>                 | 1 (4.3%)             | 0                     |
| <i>Trueperella pyogenes</i>          | 0                    | 1 (4.5%)              |
| <i>Enterococcus faecalis</i>         | 0                    | 1 (4.5%)              |
| <b>Gram-negative</b>                 |                      |                       |
| <i>Acinetobacter Iwoffii</i>         | 1 (4.3%)             | 0                     |
| <i>Psychrobacter phenylpyruvicus</i> | 1 (4.3%)             | 0                     |
| Unidentified rods                    | 2 (8.7%)             | 0                     |
| Unidentified cocci                   | 0                    | 3 (13.6%)             |
| <b>TOTAL</b>                         | 23 (100%)            | 22 (100%)             |

399 **Fig. 1** Mild and patchy fluorescein uptake indicative of corneal abrasion in the right eye of one  
400 of the study horses.



401