

## Technical Note

# Arthroscopic Repair of Proximal Posterior Cruciate Ligament Injuries in Pediatric Patients

Gabriele Pisanu, M.D., João Luís Moura, M.D.,  
Adnan Saithna, M.B.Ch.B., M.Sc., Dip.S.E.M., F.R.C.S.(T&O), and  
Bertrand Sonnery-Cottet, M.D.

**Abstract:** A renewed interest in arthroscopic knee ligament repair is emerging as a result of diagnostic and technical improvements. In pediatric patients with posterior cruciate ligament (PCL) injury, surgical reconstruction is rarely considered as an option because of the risk of iatrogenic physeal injury. In this Technical Note, we describe an arthroscopic surgical repair technique of PCL proximal avulsions in pediatric patients. The main reasons to consider arthroscopic PCL repair in this population include minimal surgical morbidity, preservation of the complex biomechanical properties of the native ligament, the small diameter of the bone tunnels, the physeal respecting nature of the procedure, the absence of graft harvesting, and the absence of fixation devices. The indications for this technique are limited to patients with an acute proximal PCL avulsion. Investigation performed from at Centre Orthopédique Santy, FIFA Medical Center of Excellence, Lyon, France.

Recent literature demonstrates that pediatric knee ligament injuries are being reported with increasing frequency resulting from higher levels of sports participation.<sup>1,2</sup> Despite that, posterior cruciate ligament (PCL) injuries in skeletally immature patients are extremely rare and not well studied. They can occur in isolation or in association with multiligament injuries.<sup>3</sup>

In adult patients, nonoperative treatment is often the first-line approach for isolated PCL injuries. Typically, only those who fail rehabilitation are considered for

PCL reconstruction. In pediatric patients, additional reasons to avoid surgical management include the risk of a physeal injury (either from drilling of tunnels or from the fixation system) and the risk of reoperation for implant removal.<sup>3</sup> However, the literature contains small series and case reports of young patients treated surgically for PCL injury in selected cases,<sup>3-5</sup> but subsequent important limb length discrepancy is reported.<sup>4</sup>

When operative treatment is indicated, the type of surgery depends on the pattern of the PCL tear. Distal avulsions are treated as a separate group because they are typically fracture fixations (open or arthroscopic) rather than a ligamentous procedure.<sup>6</sup> In contrast, the surgical management of midsubstance tears is with PCL reconstruction, whereas proximal avulsions and femoral “peel-off” injuries can be treated with arthroscopic primary repair.<sup>6-8</sup> Most of the techniques for PCL arthroscopic repair described in the literature are performed as transosseous repairs through 2 distal femoral bone tunnels or using suture anchors.<sup>6,8-10</sup> In this Technical Note, we describe the arthroscopic repair technique for proximal PCL soft-tissue tears or avulsions in pediatric patients, without the risk of damage to femoral physes and without using fixation devices.

## Surgical Technique

This technique for arthroscopic repair is indicated only for proximal, soft-tissue tear or avulsion PCL

*From the Centre Orthopédique Santy (G.P., J.L.M., B.S.-C.), FIFA Medical Centre of Excellence, Hôpital Privé Jean Mermoz, Groupe Ramsay GDS, 69008 Lyon, France; Advanced Orthopedics and Sports Medicine (A.S.), Kansas City, Missouri, U.S.A.; and School of Science and Technology (A.S.), Clifton Campus, Nottingham Trent University, Nottingham, United Kingdom.*

*The authors report the following potential conflicts of interest or sources of funding: A.S. reports personal fees from Arthrex and Smith & Nephew, outside the submitted work. B.S.-C. is a paid consultant, receives royalties and research support, and has made presentations for Arthrex. Full ICMJE author disclosure forms are available for this article online, as [supplementary material](#).*

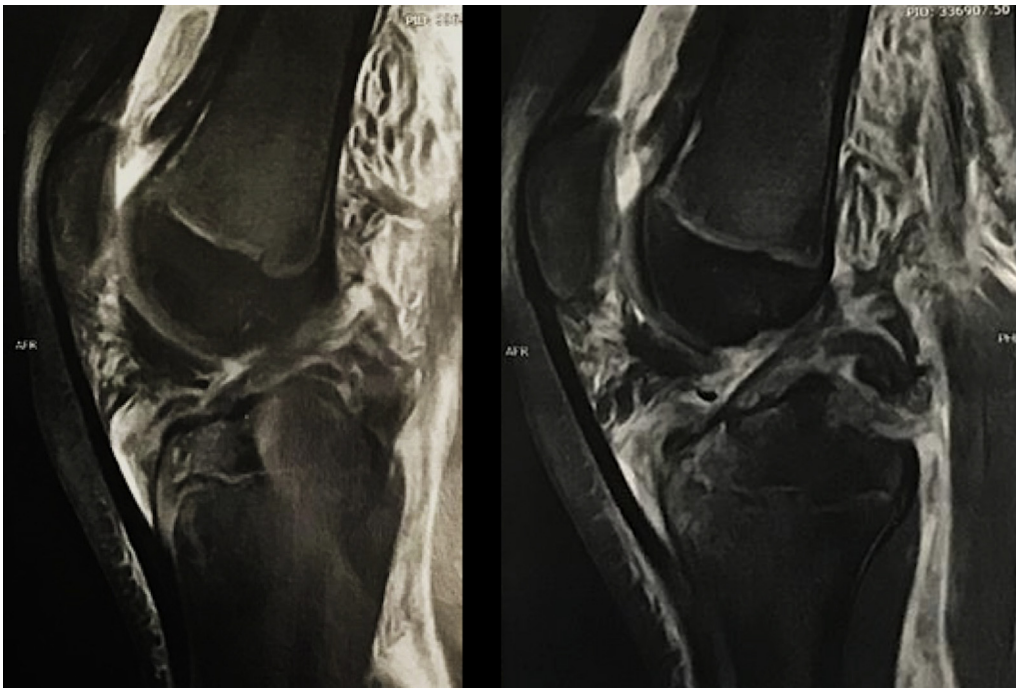
*Received January 23, 2019; accepted March 3, 2019.*

*Address correspondence to Bertrand Sonnery-Cottet, M.D., Centre Orthopédique Santy, FIFA Medical Centre of Excellence, Hôpital Privé Jean Mermoz, Groupe Ramsay GDS, 69008 Lyon, France. E-mail: [sonnerycottet@aol.com](mailto:sonnerycottet@aol.com)*

© 2019 by the Arthroscopy Association of North America. Published by Elsevier. This is an open access article under the CC BY-NC-ND license (<http://creativecommons.org/licenses/by-nc-nd/4.0/>).

2212-6287/1992

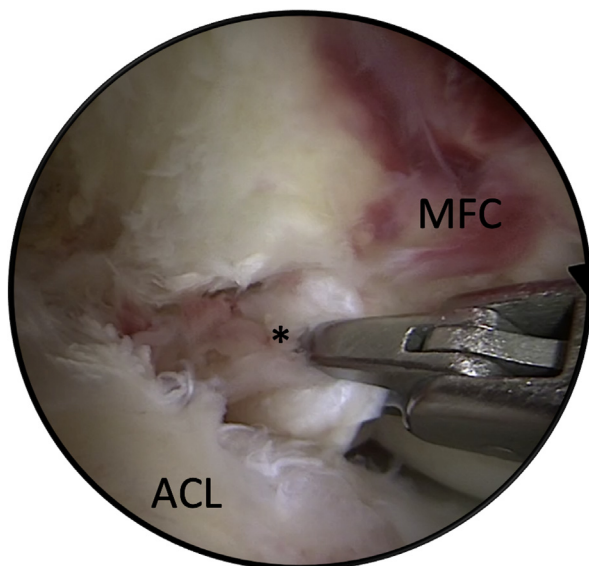
<https://doi.org/10.1016/j.eats.2019.03.003>



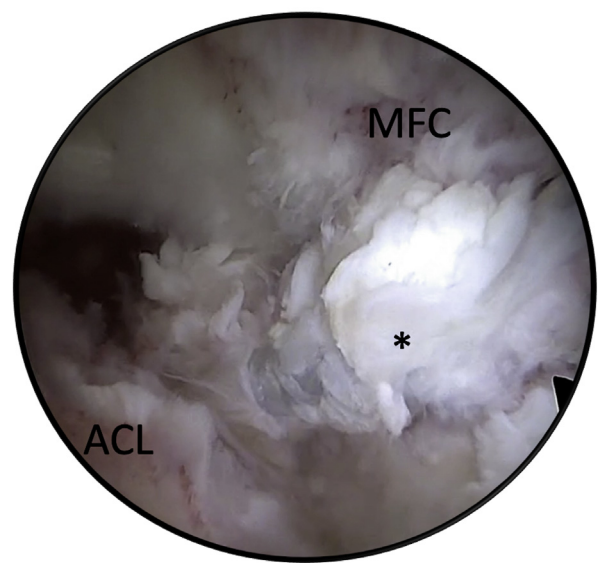
**Fig 1.** Sagittal images of the right knee with 2 successive slices demonstrating proximal posterior cruciate ligament tear.

injury patterns (Video 1), but can be performed in both isolated or multiligament injury scenarios. The magnetic resonance imaging scan must show a femoral avulsion of the PCL with a normal distal tibial insertion on the sagittal plane (Fig 1); however, arthroscopic evaluation is necessary to confirm the feasibility to proceed with ligament repair. This evaluation is mainly

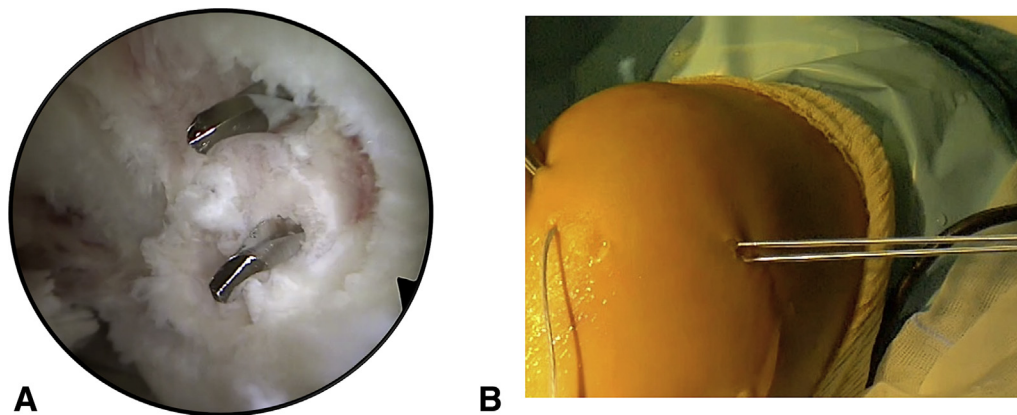
focused on confirming that the remnant can be reapproximated to the femoral PCL footprint and that the stump demonstrates good tissue quality. If these conditions are not met, then PCL repair should not be attempted and the procedure should be changed. A delay of more than 2-3 weeks after injury could result in a time-dependent decrease in tissue quality and remnant length.<sup>6</sup>



**Fig 2.** Right knee; anterolateral portal viewing. Mobilization of the PCL stump toward its femoral insertion using a grasper placed through the Gillquist portal. \*PCL. (ACL, anterior cruciate ligament; MFC, medial femoral condyle; PCL, posterior cruciate ligament.)



**Fig 3.** Right knee; anterolateral portal viewing). Sutured PCL remnant. \*PCL. (ACL, anterior cruciate ligament; MFC, medial femoral condyle; PCL, posterior cruciate ligament.)



**Fig 4.** Right knee. (A) Anterolateral portal view of femoral posterior cruciate ligament footprint. (B) Extra-articular view of the 2.4-mm pin positioned through the medial femoral condyle.

The patient, with a tourniquet around the thigh, is positioned supine on an operating table in the standard arthroscopy position. A bumper is placed at the lateral side of the thigh and another at the foot to hold the knee at 90° of flexion.

After establishing high anterolateral and anteromedial portals, the feasibility of repair is assessed by confirming a proximal avulsion of the PCL. If the PCL remnant requires gentle debridement to mobilize it, this can be performed through a posteromedial portal. The free end of the remnant is inspected to confirm adequate tissue quality and a grasper is used to confirm that the stump can be reapproximated to the femoral footprint (Fig 2). During this process, it is important to reduce any posterior tibial sag with an anterior drawer force to avoid gaining an incorrect impression that the remnant is too short for repair.

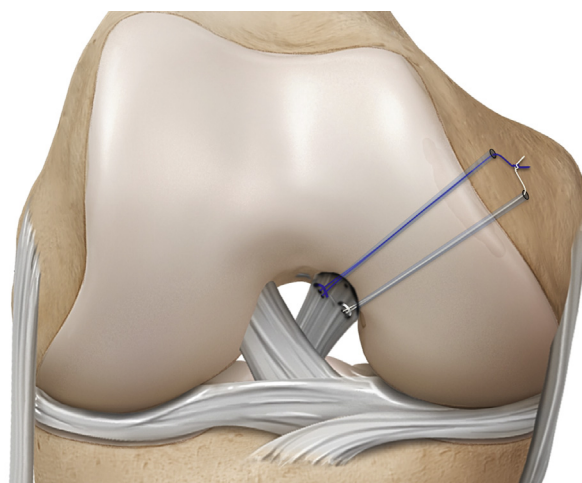
For optimum management of the remnant, a central transpatellar tendon portal (Gillquist) is made. Through this, portal a grasper is used to keep the PCL stump gently tensioned. A reloadable knee suture passing device (Scorpion; Arthrex) is inserted via the anteromedial portal, and used to pass 2 nonabsorbable polyester sutures (FiberWire and TigerWire No. 2; Arthrex) through the stump. Each suture is sequentially reloaded into the device and passed through the stump to create a Cushing-type stitch to increase the strength of the pullout (Fig 3).

It is important to pass the sutures as distal as possible within the stump to capture the best-quality tissue. At least 2 consecutive passages are made with each suture but we suggest to perform 3, if it is possible. It is important to avoid cutting or damaging the previous suture passage, so it is mandatory to reposition the suture device if unexpected resistance is felt during suture passage.

When a valid purchase of the stump is obtained, the free suture limbs are protected by retrieving them through the transpatellar portal while the femoral footprint is partially debrided and roughened with an

arthroscopic shaver. The outside-in femoral guide (Arthrex) is inserted at this location and positioned at the footprint of the PCL. The arthroscope is placed in the medial gutter and the optimal medial entrance point for the femoral tunnel is localized with a needle, taking care to position the entry point in the distal part of the medial gutter to avoid the physis. Two 2.4-mm tunnels are drilled obliquely in the distal femoral epiphysis, in a medial to lateral fashion (Fig 4).

A suture retriever with a capture loop (Arthrex), is placed in each femoral bone tunnel and 1 suture end from each type of suture are then retrieved via each tunnel. This results in a single TigerWire and FiberWire strand in each tunnel. With the knee flexed at 90°, and with an anterior-drawer force applied, the sutures are tied over the bone bridge between the 2 femoral tunnels (Fig 5), without using any devices and taking care to avoid interposition of tissues. Pearls and pitfalls of the surgical technique are given in Table 1.



**Fig 5.** Right knee. The limbs of the FiberWire and TigerWire are knotted onto the bone bridge in the medial gutter under arthroscopic control.

**Table 1.** Surgical Steps and Pearls and Pitfalls for the Arthroscopic PCL Repair in Pediatric Patients

Surgical Step	Pearls	Pitfalls
Remnant debridement	Debridement via posteromedial portal allows mobilization	Aggressive debridement of the remnant resulting in shortening
Notch debridement	Visualize the femoral footprint without complete debridement of the femoral remnant	Extensive debridement may lead to inappropriate femoral tunnel placement
Length test	Apply an anterior drawer force	Failure to correct posterior sag may give a false impression of insufficient length for repair
PCL suture	Pass 2 sutures through the tissue multiple times to obtain a robust purchase of the ligament	Placement of peripheral sutures risks cut-out and imprecise placement can result in damaging previously passed sutures
Femoral tunnel	With a needle localize the femoral tunnel in the medial gutter. Perform microfractures around the footprint to improve ligament-bone healing	Entry points of the femoral tunnels positioned in the distal area of the medial gutter to avoid physis
Management of associated lesions	Assessment of the posterior root and posterior horn of the menisci	Addressing associated lesions is more complicated after PCL fixation and should be performed first
Fixation of the suture of the graft	The PCL sutures are fixed at 90° of knee flexion with anterior-drawer maneuver	Locking knots with interposed tissue

PCL, posterior cruciate ligament.

### Postoperative Course

A posterior long leg splint is positioned and maintained for 3 weeks without weight bearing. At 3 weeks, a hinged knee brace and progressive range-of-motion exercises are allowed. The brace is maintained for 12 months and return to competitive sport is allowed at 1 year from surgery.

### Discussion

The first case series of arthroscopic PCL repair was reported by Wheatley et al.,<sup>9</sup> who reported encouraging results with respect to postoperative stability and functional outcomes. Ross et al.<sup>10</sup> also reported comparable results. DiFelice et al.<sup>6</sup> described a modification of Wheatley's technique, using shoulder arthroscopic sets and a button to decrease the tension on the bone bridge. Rosso et al.<sup>8</sup> described a technique for proximal PCL tears using anchors instead of transfemoral tunnel.

The main reasons to consider arthroscopic PCL repair in pediatric patients are similar to those for anterior cruciate ligament repair. They include the potential advantages of reduced surgical morbidity, enhanced early recovery, the preservation of nerves and intrinsic

cell populations, the native physiology, and the preservation of the biomechanical properties of the native ligament (Table 2). Additional benefits concern the small diameter of the bone tunnels, avoidance of physeal injury, the absence of graft harvesting and the absence of fixation devices that are all useful issues if a revision is required in case of a rerupture. Nevertheless, the field of application of this technique is limited to patients with an acute proximal PCL avulsion or tear. The decision to perform PCL repair is made intraoperatively on confirmation that the stump can be reapproximated to the femoral footprint. For that reason, an alternative treatment option should always have been presented and discussed with the patient. Furthermore, long-term data and consistent clinical evaluation are lacking for this specific technique and these issues must also be discussed during preoperative consultation with the patient regarding the risks and benefits of the procedure.

### References

1. Beck NA, Lawrence JTR, Nordin JD, DeFor TA, Tompkins M. ACL tears in school-aged children and adolescents over 20 years. *Pediatrics* 2017;139, e20161877.
2. Defrancesco CJ, Storey EP, Shea KG, Kocher MS, Ganley TJ. Challenges in the management of anterior cruciate ligament ruptures in skeletally immature patients. *J Am Acad Orthop Surg* 2018;26:e50-e61.
3. Kocher MS, Shore B, Nasreddine AY, Heyworth BE. Treatment of posterior cruciate ligament injuries in pediatric and adolescent patients. *J Pediatr Orthop* 2012;32:553-560.
4. Sørensen OG, Faunø P, Christiansen SE, Lind M. Posterior cruciate ligament reconstruction in skeletal immature children. *Knee Surg Sports Traumatol Arthrosc* 2017;25:3901-3905.

**Table 2.** Advantages and Disadvantages of the Arthroscopic Posterior Cruciate Ligament Repair in Pediatric Patients

Advantages	Disadvantages
No donor site morbidity	Limited indication
All autograft options available for other ligament reconstructions	Insufficient long-term data
All arthroscopic procedure	Only suitable for acute injuries
No fixation devices to remove	
Small bone tunnel	
Physeal respecting	
Preservation of native cells	
Low-cost procedure	

5. Bovid KM, Salata MJ, Vander Have KL, Sekiya JK. Arthroscopic posterior cruciate ligament reconstruction in a skeletally immature patient: A new technique with case report. *Arthroscopy* 2010;26:563-570.
6. DiFelice GS, Lissy M, Haynes P. When to arthroscopically repair the torn posterior cruciate ligament. *Clin Orthop Relat Res* 2012;470:861-868.
7. van der List JP, DiFelice GS. Arthroscopic primary posterior cruciate ligament repair with suture augmentation. *Arthrosc Tech* 2017;6:e1685-e1690.
8. Rosso F, Bisicchia S, Amendola A. Arthroscopic repair of "peel-off" lesion of the posterior cruciate ligament at the femoral condyle. *Arthrosc Tech* 2014;3:e149-e154.
9. Wheatley WB, Martinez AE, Sacks T, et al. Arthroscopic posterior cruciate ligament repair. *Arthroscopy* 2002;18:695-702.
10. Ross G, Driscoll J, McDevitt E, Scheller A. Arthroscopic posterior cruciate ligament repair for acute femoral "peel off" tears. *Arthroscopy* 2003;19:431-435.