







# The dilemma of the disappeared colorectal liver metastasis: systematic review of reviews and evidence gap map

Ahmed Nassar<sup>1,2</sup> , Sorin Cimpean<sup>3</sup>, Amir Abdelhamid<sup>1,2</sup> , Robert P. Jones<sup>4</sup>, Roger Wahba<sup>5</sup>, Guido Fiorentini<sup>6</sup>, Luca Aldrighetti<sup>7</sup> , Catherine Teh<sup>8,9,10</sup> , Ruslan Alikhanov<sup>11</sup>, John Hammond<sup>12</sup>, Michael Silva<sup>13</sup>, Areeg Abdelmabod<sup>1,2</sup>, Stephanie Truant<sup>14</sup>, Alessandro Ferrero<sup>15</sup>, Christian Stuesson<sup>16</sup> , Irfan Ahmed<sup>1,2</sup>, Mudassar Ghazanfar<sup>1,2</sup>, Nobuyuki Takemura<sup>17</sup>, Timothy M. Pawlik<sup>18</sup>  and Mohamed Bekheit<sup>1,2,19,\*</sup>

<sup>1</sup>Institute of Medical Sciences, University of Aberdeen, Scotland, UK

<sup>2</sup>Department of Surgery, NHS Grampian, Scotland, Aberdeen, UK

<sup>3</sup>Department of Surgery, CHU - St Pierre, Brussels, Belgium

<sup>4</sup>Northwest Hepatobiliary Unit, Department of Surgery, Liverpool University Hospitals NHS Foundation Trust, Liverpool, UK

<sup>5</sup>Departement of General, Visceral, Cancer and Transplantation Surgery, University of Cologne, Faculty of Medicine and University Hospital Cologne, Cologne, Germany

<sup>6</sup>Division of Hepatobiliary and Pancreas Surgery, Mayo Clinic Rochester, Rochester, USA

<sup>7</sup>Hepatobiliary Surgery Division, San Raffaele Hospital, Milan, Italy

<sup>8</sup>Department of Surgery, Makati Medical Center, Makati Metro Manila, Philippines

<sup>9</sup>Department of Surgery, National Kidney & Transplant Institute, Quezon, Philippines

<sup>10</sup>Department of Surgery, St Luke's Medical Center, Quezon, Philippines

<sup>11</sup>Moscow Clinical Scientific Center, Department of liver and pancreatic surgery and Transplantation, Russia

<sup>12</sup>Department of HPB and Transplantation, Freeman Hospital, Newcastle upon Tyne, Newcastle, UK

<sup>13</sup>Department of Surgery, Oxford University Hospital, Oxford, UK

<sup>14</sup>Department of Surgery, Centre Hospitalier Régional Universitaire de Lille: Lille, Nord-Pas-de-Calais, Lille, France

<sup>15</sup>Department of Surgical Oncology, Mauriziano Hospital, Turin, Italy

<sup>16</sup>Division of Surgery, Department of Clinical Science, Intervention and Technology (CLINTEC), Karolinska Institutet and Karolinska University Hospital, Stockholm, Sweden

<sup>17</sup>Department of Surgery, National Center for Global Health and Medicine (NCGM), Tokyo, Japan

<sup>18</sup>Department of Surgery, The Ohio State University Wexner Medical Center, Ohio, USA

<sup>19</sup>Surgical Unit, HPB Integrated Center of Care, Elite Integrated Centers of Excellence, Alexandria, Egypt

\*Correspondence to: Mohamed Bekheit, Department of Surgery, Aberdeen Royal Infirmary, Department of Surgery, Forehill Health Campus, Aberdeen AB252ZN, UK (e-mail: Dr\_mohamedbekheit@hotmail.com)

Dear Editor

The 'disappearing colorectal liver metastasis' (dCRLM) is becoming an increasingly common finding. There is no consensus on its management. The aim of this study was to provide a summary of evidence on the management strategies of dCRLM.

The literature search was performed by an expert Information Specialist, Royal College of Surgeons of England Library and Archives Team aiming to identify all relevant systematic reviews through MEDLINE, Embase, and the Cochrane Database of Systematic Reviews from their inception till the end of January 2021 (Table S1). Literature in English was searched for with no restriction on the dates.

The main outcomes of interest were overall survival (OS), disease-free survival (DFS) in treated and non-treated dCRLM, complete pathological response (CPR) in resected dCRLM, and sensitivities of different imaging modalities (Table S2). Non-English studies and studies that included patients younger than 18 years old were excluded.

This review included three systematic reviews, two narrative reviews, and one overview (Fig. S1 and Table S3). An evidence gap map is shown in Fig. S2. The risk of bias assessment according to ROBIS tool is shown in Table S4. The included patients had a median (range) age of 58 (30–83) years old<sup>1,2</sup>. Total number of colorectal liver metastasis (CRLM) was 4174<sup>1–4</sup> and the average (mean) number of dCRLM per patient was 2.7<sup>1,2,4</sup>.

Different studies used different preoperative imaging protocols relying on one or more imaging modalities. Two systematic reviews pointed out that most studies relied on contrast enhanced CT (CE-CT) to define dCRLM<sup>1,2</sup>. Others based the definition on different preoperative imaging modalities<sup>3,5</sup>.

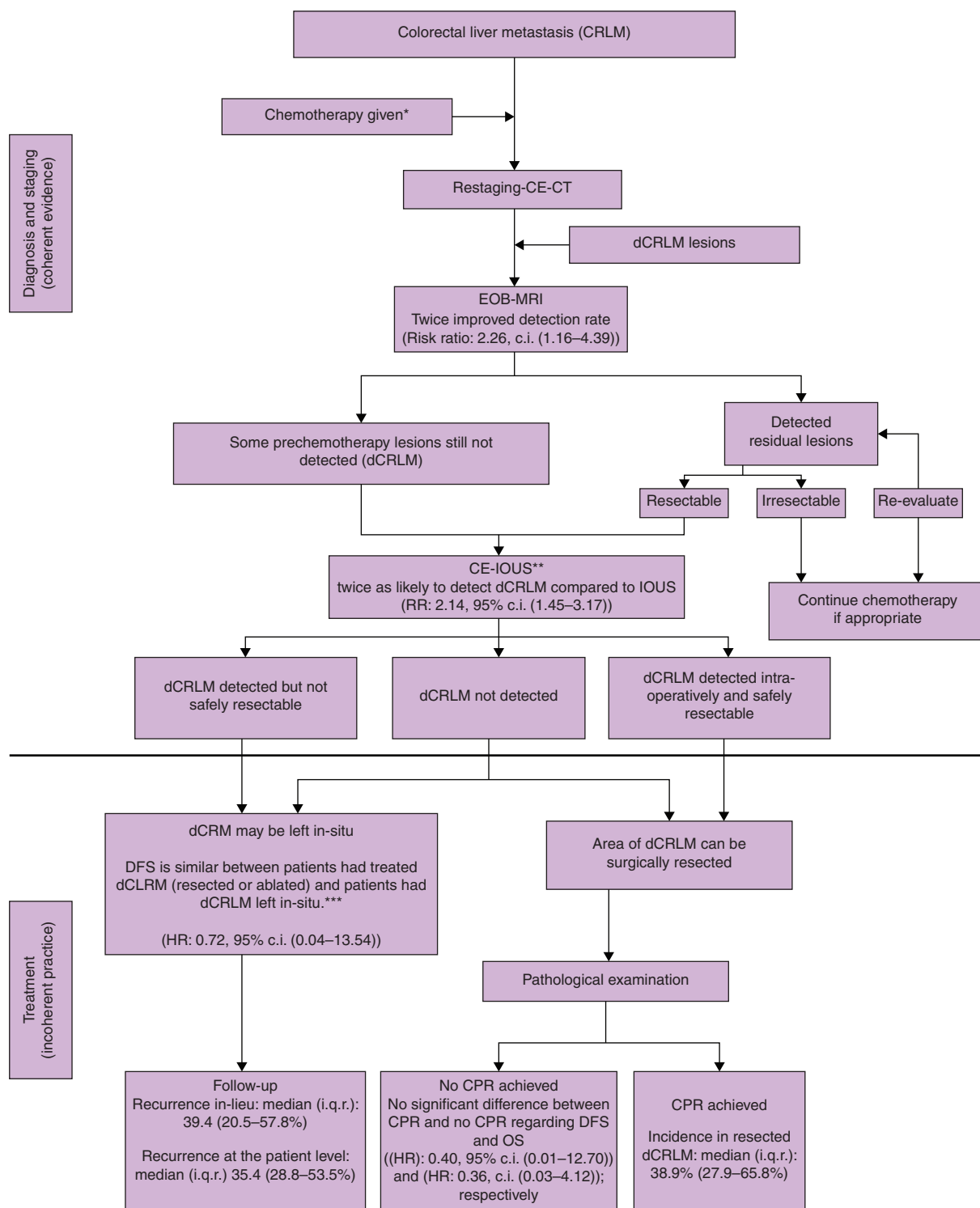
Table S5 shows details of imaging modalities across studies and the numbers of CRLM detected/disappeared.

Intraoperative ultrasound imaging alone or with contrast enhancement (IOUS and CE-IOUS) was twice as likely to detect dCRLM as preoperative imaging (risk ratio 2.52, 95 per cent c.i. 1.80 to 3.50). Gadoteric acid (Gd-EOB-DTPA) enhanced magnetic resonance imaging (EOB-MRI) was twice as likely to detect

Received: January 17, 2022. Revised: February 05, 2022. Accepted: March 15, 2022

© The Author(s) 2022. Published by Oxford University Press on behalf of BJS Society Ltd.

This is an Open Access article distributed under the terms of the Creative Commons Attribution-NonCommercial License (<https://creativecommons.org/licenses/by-nc/4.0/>), which permits non-commercial re-use, distribution, and reproduction in any medium, provided the original work is properly cited. For commercial re-use, please contact [journals.permissions@oup.com](mailto:journals.permissions@oup.com)



**Fig. 1** Algorithm demonstrating diagnosis and treatment of disappearing colorectal liver metastasis (dCRLM)

\*Fiducial markers can facilitate intra-operative localisation after chemotherapy for lesions at high risk of developing dCRLM. \*\*CE-IOUS and EOB-MRI detect comparable number but different lesions. Hence, combined imaging modalities has higher detection rate than individual imaging. \*\*\*Due to wide c.i., recommendation whether to resect dCRLM or leave in-situ cannot be established. EOB-MRI, gadoxetic acid (Gd-EOB-DTPA) enhanced magnetic resonance imaging; CE-CT, contrast enhanced CT; CE-IOUS, contrast enhancement Intraoperative ultrasound; IOUS, Intraoperative ultrasound; RR, risk ratio; CPR, complete pathological response; dCRLM, disappearing colorectal liver metastasis; DFS, disease free survival; OS overall survival.

dCRLM compared with CE-CT (risk ratio 2.26, 95 per cent c.i. 1.16 to 4.39). Intraoperatively, CE-IOUS was twice as likely to detect dCRLM compared with IOUS (risk ratio 2.14, 95 per cent c.i. 1.45 to 3.17) (Fig. S3).

Excluding those patients having hepatic artery infusion chemotherapy (HAI), CPR was achieved in 389 (42.3 per cent) out of 919 surgically resected dCRLMs (median (interquartile range; i.q.r.) 38.9 (27.9–65.8) per cent, Table S6). CPR was achieved in 44

(97.8 per cent) of 45 patients who had surgical resection of dCRLM after HAI.

Local recurrence was reported in 153 (32.4 per cent) dCRLMs out of 472 lesions with a median (i.q.r.) 39.4 (20.5–57.8 per cent). The median (i.q.r.) follow-up interval was 31 (24.5–42.5) months. (Table S6).

There was no significant difference in DFS or OS whether the pathological analysis of resected dCRLM showed CPR or not (hazard ratio (HR) 0.40, 95 per cent c.i. 0.01 to 12.70), (HR 0.36, 95 per cent c.i. 0.03 to 4.12) respectively. DFS in treated (resected or ablated) patients with dCRLM was similar to patients under surveillance (HR 0.72, 95 per cent c.i. 0.04 to 13.54) (Fig. S4).

EOB-MRI demonstrated consistent superior sensitivity for detection of dCRLM unlike the treatment strategies, where no consistent approach was adopted (Fig. 1).

dCRLM remains a complex topic and its incidence is likely to increase with advances in chemotherapy. The authors have established the 'outcome of liver intervention or surveillance in disappearing colorectal liver metastases (LORDS-M)' study group and a bespoke secure database for individual patient data collection as a means to provide robust base for collaborative research on the topic. The registration portal to this database is through the link (<https://redcap.abdn.ac.uk/surveys/?s=X3TJCWPWTM>).

At present the definition of dCRLM should be based on EOB-MRI as it seem to be the most sensitive preoperative imaging. Further research is still required to determine the best management strategy for patients with dCRLM.

**Disclosure.** The authors declare no conflict of interest

## Supplementary material

Supplementary material is available at *BJS Open* online.

## Data availability

The data underlying this article are available with the corresponding and first authors. The corresponding author can provide copy of the data upon request.

## References

1. Barimani D, Kauppila JH, Stureson C, Sparrelid E. Imaging in disappearing colorectal liver metastases and their accuracy: a systematic review. *World J Surg Oncol* 2020;**18**:264
2. Tsilimigras DI, Ntanasis-Stathopoulos I, Paredes AZ, Moris D, Gavriatopoulou M, Cloyd JM et al. Disappearing liver metastases: a systematic review of the current evidence. *Surg Oncol* 2019;**29**:7–13
3. Araujo RLC, Milani JM, Armentano DP, Moreira RB, Pinto GSF, de Castro LA et al. Disappearing colorectal liver metastases: strategies for the management of patients achieving a radiographic complete response after systemic chemotherapy. *J Surg Oncol* 2020;**121**:848–856
4. Kuhlmann K, van Hilst J, Fisher S, Poston G. Management of disappearing colorectal liver metastases. *Eur J Surg Oncol* 2016;**42**:1798–1805
5. Lucidi V, Hendlisz A, Van Laethem JL, Donckier V. Missing metastases as a model to challenge current therapeutic algorithms in colorectal liver metastases. *World J Gastroenterol* 2016;**22**:3937–3944