

Received Date : 06-Nov-2015

Revised Date : 22-Dec-2015

Accepted Date : 23-Dec-2015

Article type : Commentary

Retained Placenta: will medical treatment ever be possible?

Running Headline: Retained placenta and medical treatment

Achier D. Akol & Andrew D. Weeks

Department of Women's and Children's Health, University of Liverpool, UK

Corresponding author

Andrew Weeks

Sanyu Research Unit, Department of Women's and Children's Health, University of Liverpool, c/o 1st Floor, Liverpool Women's Hospital, Crown Street, Liverpool L8 7SS, UK

E-mail: aweeks@liv.ac.uk

Conflicts of Interests

None of the authors have any conflicts of interest regarding either financial or personal relationship to declare.

Abstract

The standard treatment for retained placenta is manual removal whatever its subtype (adherens, trapped or partial accreta). Although medical treatment should reduce the risk of anesthetic and surgical complications, they have not been found to be effective. This may be due to the contrasting uterotonic needs of the different underlying pathologies. In placenta

This article has been accepted for publication and undergone full peer review but has not been through the copyediting, typesetting, pagination and proofreading process, which may lead to differences between this version and the Version of Record. Please cite this article as doi: 10.1111/aogs.12848

This article is protected by copyright. All rights reserved.

Accepted Article

adherens, oxytocics have been used to contract the retro-placental myometrium. However, if injected locally through the umbilical vein, they bypass the myometrium and perfuse directly into the venous system. Intravenous injection is an alternative, but exacerbates a trapped placenta. Conversely, for trapped placentas, a relaxant could help by resolving cervical constriction, but would worsen the situation for placenta adherens. This confusion over medical treatment will continue unless we can find a way to diagnose the underlying pathology. This will allow us to stop treating the retained placenta as a single entity and delivering targeted treatments.

Key Words

Retained placenta, medical treatment, way through medical treatment, delivery, postpartum hemorrhage

Abbreviations

RP Retained placenta

Key Message

Way through the confusion of medical treatment for the retained placenta.

The scale of the problem

Obstetric hemorrhage remains a leading cause of maternal death worldwide (1) and retained placenta (RP) is a significant contributor (2). The incidence appears to be related to intrapartum intervention as rates increase with both time and health system development (3). The rate currently in Europe is around 2-3%. If RP is not treated, it may lead to maternal death due to postpartum hemorrhage or sepsis. Historically, in the UK, RP led to the deaths of around 7 women per 100,000 births (4), and in modern African settings, with delayed access for manual removal, the case fatality rate remains around 1% (5). It is clear however, that many RPs will spontaneously deliver with time. Indeed, in the placebo arm of the largest randomized trial to date, 38% delivered spontaneously over the hour following recruitment

with 10% having blood loss of over 1000mls (6) . Thus, there is a careful risk-benefit balance between waiting, which allows more spontaneous deliveries, and intervening to prevent blood loss and sepsis. It has been suggested that when considering PPH the optimal time for manual removal is 18 minutes, (7), but does not take into consideration the adverse medical, neonatal or psychological effects of manual removal of placenta.

Herman et al first documented the ultrasound findings in the normal third stage of labor and placenta adherens (8) and went on to describe the use of ultrasound for the diagnosis of the three known subtypes: Placenta Adherens, Partial Accreta and Trapped Placenta (9). Following this description however there has been no formal analysis of the utility of ultrasound in RP.

Currently, the standard treatment of RP is manual removal whatever the subtype, even though this has anesthetic and surgical risks. Whilst treating RP with drugs would remove many of these risks, medical therapies have not been well investigated, partly because of a current inability to rapidly and accurately distinguish the various forms of RP on the labor ward. The use of medical therapies to treat RP, irrespective of the underlying subtype, has led to confusion.

Conflicting guidance

1. Umbilical vein injection of oxytocin

Following the hypothesis that the pathogenesis of the RP adherens is due to the failure of contraction of the retro-placental myometrium (8), umbilical vein injection (UVI) of oxytocics to counteract that inhibition seems to be a plausible remedy. However, conflicting advice on the use of UVI oxytocin to treat the RP has been issued by the National Institute of Health and Care Excellence (NICE) group in the UK. They recommended its use in 2007 because of Cochrane Reviews that showed that it was associated with significantly fewer manual removals when compared with UVI saline (10). Now, NICE has changed its advice and no longer recommends the use of UVI oxytocin following a cost analysis and a finding that it tends to be associated with severe postpartum hemorrhage despite being an oxytocic (11). This is in keeping with other large controlled trials that evaluated UVI oxytocin and demonstrated lack of significant overall benefit including the Release Trial (6). Likewise, the administration of intravenous oxytocic agents to deliver a RP is not recommended unless the woman is bleeding excessively, although there is no conclusive evidence on this.

2. UVI Prostaglandins

There is also frustration with the use of other UVI agents. Meta-analysis has demonstrated a significant reduction in the need for manual removal of the placenta (MROP) following UVI prostaglandin when compared to UVI oxytocin (10). Randomized controlled trials also showed that intravenous infusion of sulprostone also reduced the need for MROP when compared to placebo (12). However, these trials were few, with small sample sizes and their effects were inconsistent or statistically insignificant. Therefore, UVI Prostaglandins are currently not recommended.

3. Nitroglycerin

The use of nitroglycerine for the trapped placenta is also clouded with uncertainty. One trial showed sublingual nitroglycerine to be associated with a significant reduction in manual removal of the placenta, when compared with placebo (13). However, this trial involved only 24 women and a subsequent larger study by the same team showed no significant benefit (14). Another small trial of intravenous nitroglycerine also demonstrated no benefit (15). We await with interest the outcome of the UK-wide randomized controlled trial on the use of glycerin trinitrate for the RP (GOT-IT Trial).

Why does the optimal management of RP continue to elude us?

It is likely that the various medical treatments for RP do not work for a number of reasons.

The first reason is the lack of accurate diagnosis of the RP subtypes. Although RP is a group of pathologies, it has a common presentation and has been therefore treated as a single entity. It is important to get the type of RP right before prescribing uterotonics instead of relaxants. For, whilst uterotonics like oxytocin can treat placenta adherens by contracting the retro-placental myometrium, they are likely to exacerbate trapped placenta by increasing cervical constriction. In contrast, relaxants can counteract uterine or cervical constriction to deliver a trapped placenta, but they would worsen placenta adherens and possibly precipitate hemorrhage by increasing uterine relaxation. Neither uterotonics nor relaxants can treat a partial accreta, but continuous cord traction on an accreta, following a false impression that a medication administered might help, could also lead to severe hemorrhage or uterine inversion.

The second reason may be that UVI agents probably go to the wrong place. After passing up the umbilical vein they perfuse through the placenta villi into the radial veins in the uterus without reaching the retro-placental myometrium. It is only on the second pass around the body that they reach the myometrial capillaries and initiate the desired myometrial contraction. By this stage the concentration is likely to be very low and no longer directed at just the retroplacental myometrium (see Figure 1).

Conclusion

Effective medical therapy for RP should avoid the surgical and anesthetic risks associated with the current standard treatment of manual removal. However it can only be made to work if the reasons for its failure are adequately addressed. UVI may not directly enter the myometrial capillary bed and alternative forms of directed treatment, possibly using nanoparticles, may provide a better way of delivering oxytocics to the retro-placental myometrium. But the main problem is our inability to differentiate between the various pathologies underlying RP, each of which has a different, and conflicting, treatment requirement. The confusion over medical treatment will continue unless we stop treating the RP as a single entity and start tailoring the treatment to the underlying pathology. This will take an effective way of diagnosing the type – probably using a mixture of uterine ultrasound and Doppler of the uterine vessels. . Until then, the medical treatment of RP is likely to continue to elude us.

References:

1. Say L, Chou D, Gemmill A, Tunçalp Ö, Moller A-B, Daniels J, et al. Articles: Global causes of maternal death: a WHO systematic analysis. *Lancet Glob Health*. 2014;2:e323-e33.
2. Moodley J, Pattinson RC, Fawcus S, Schoon MG, Moran N, Shweni PM. The Confidential Enquiry into Maternal Deaths in South Africa: a case study. *BJOG*. 2014;121 Suppl 4:53-60.
3. Cheung WM, Hawkes A, Ibish S, Weeks AD. The retained placenta: historical and geographical rate variations. *J Obstet Gynaecol*. 2011;31(1):37-42.
4. Kerr RS, Weeks AD. Lessons from 150 years of UK maternal hemorrhage deaths. *Acta Obstet Gynecol Scand*. 2015;94(6):664-8.

5. John CO, Orazulike N, Alegbeleye J. An appraisal of retained placenta at the university of port harcourt teaching hospital: a five-year review. *Nigerian J Med.* 2015;24(2):99-102.
6. Weeks AD, Alia G, Vernon G, Namayanja A, Gosakan R, Majeed T, et al. Umbilical vein oxytocin for the treatment of retained placenta (Release Study): a double-blind, randomised controlled trial. *Lancet.* 2010;375(9709):141-7.
7. Magann EF, Evans S, Chauhan SP, Lanneau G, Fisk AD, Morrison JC. The length of the third stage of labor and the risk of postpartum hemorrhage. *Obstet Gynecol.* 2005;105(2):290-3.
8. Herman A, Weinraub Z, Bukovsky I, Arieli S, Zabow P, Caspi E, et al. Dynamic ultrasonographic imaging of the third stage of labor: new perspectives into third-stage mechanisms. *Am J Obstet Gynecol.* 1993;168(5):1496-9.
9. Herman A. Complicated third stage of labor: time to switch on the scanner. *Ultrasound Obstet Gynecol.* 2000;15(2):89-95.
10. Nardin JM, Weeks A, Carroli G. Umbilical vein injection for management of retained placenta. *Cochrane Database Syst Rev.* 2011(5):CD001337.
11. National Institute for Health and Clinical Excellence, Intrapartum care: care of healthy women and their babies during childbirth. NICE clinical guideline 190. RCOG Press. [press release]. 2014.
12. van Beekhuizen HJ, de Groot AN, De Boo T, Burger D, Jansen N, Lotgering FK. Sulprostone reduces the need for the manual removal of the placenta in patients with retained placenta: a randomized controlled trial. *Am J Obstet Gynecol.* 2006;194:446-50.
13. Bullarbo M, Tjugum J, Ekerhovd E. Sublingual nitroglycerin for management of retained placenta. *Int J Gynaecol Obstet.* 2005;91(3):228-32.
14. Bullarbo M, Bokstrom H, Lilja H, Almstrom E, Lassenius N, Hansson A, et al. Nitroglycerin for management of retained placenta: a multicenter study. *Obstet Gynecol Int.* 2012;2012:321207.
15. Visalyaputra S, Prechapanich J, Suwanvichai S, Yimyam S, Permpolprasert L, Suksopoe P. Intravenous nitroglycerin for controlled cord traction in the management of retained placenta. *Int J Gynaecol Obstet.* 2011;112(2):103-6.

Legend

Figure 1. Blood flow from umbilical veins to fetal capillaries.

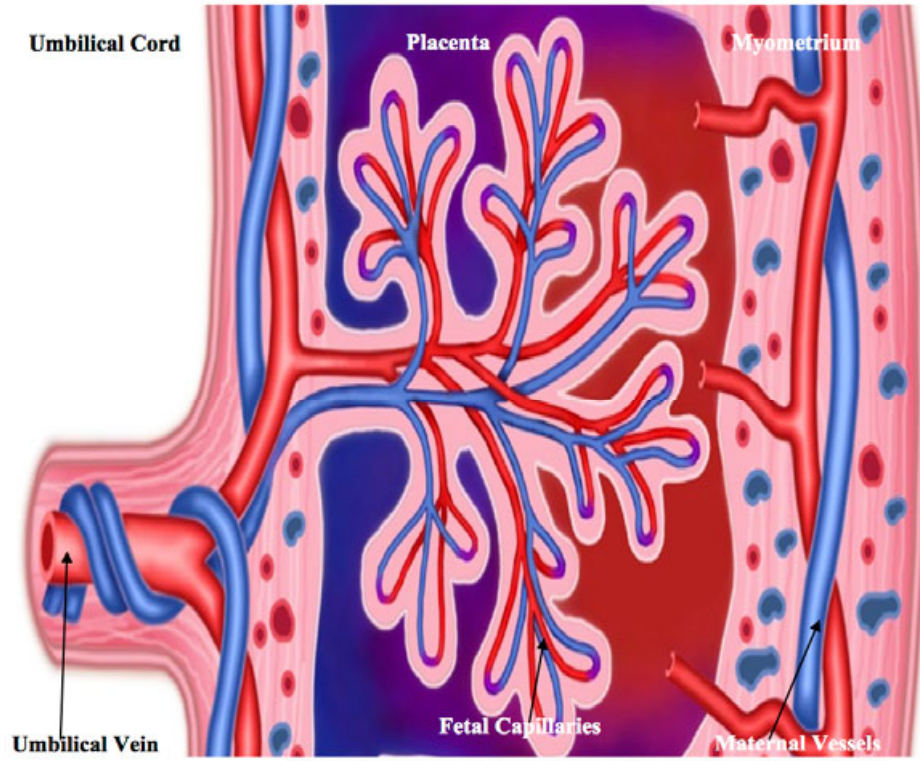


Figure 1 Blood Flow from Umbilical Vein to Fetal Capillaries