

# VetRecord CaseReports

## POSTOBSTRUCTIVE NEGATIVE PRESSURE PULMONARY OEDEMA IN A DOG

Journal:	<i>Veterinary Record Case Reports</i>
Manuscript ID	vetreccr-2019-000892.R1
Manuscript Type:	Companion or pet animals
Species:	Dogs
Date Submitted by the Author:	05-Jul-2019
Complete List of Authors:	Louro, Luís; University of Liverpool Institute of Veterinary Science, Small Animal Clinical Science Raszplewicz, Joanna; University of Liverpool School of Life Sciences, Small Animal Clinical Science Hodgkiss-Geere, Hannah; University of Liverpool Institute of Veterinary Science, Small Animal Clinical Science Pappa, Eirini; University of Liverpool Institute of Veterinary Science, Small Animal Clinical Science
Keywords:	Anaesthesia, negative pressure pulmonary oedema, brachycephalic, Intensive care, postobstructive pulmonary oedema, post-anaesthetic complications
Topics:	Anaesthesia and analgesia, Physiology, Imaging

1  
2  
3  
4  
5  
6  
7

Abstract:	<p>A four-month-old English bulldog was anaesthetised for investigation and management of chronic urinary incontinence. In the post-anaesthetic period the patient developed respiratory distress, with marked cough and increased inspiratory effort. Diagnostic imaging suggested pulmonary oedema. After excluding all other causes of cardiogenic and non-cardiogenic pulmonary oedema it was indicated that the patient developed post-anaesthetic negative pressure pulmonary oedema due to tracheal intubation with an oversized endotracheal tube leading to laryngeal swelling and obstruction. The animal was treated with oxygen supplementation, corticosteroids and <math>\beta</math>-2 adrenergic receptor agonists. The patient recovered from the event and was discharged from the hospital after forty-eight hours. This article discusses this case in further detail including other management options of negative pressure pulmonary oedema. This is the first case report focused on the pathophysiology, critical care and management of post-anaesthetic negative pressure pulmonary oedema in a dog.</p>
<p style="text-align: center;">Veterinary Record Case Reports</p>	


**Commented [CA1]:** suspected

**Commented [CA2]:** still not convinced about this – I much prefer the way it was described in the report.

SCHOLARONE™  
Manuscripts

8  
9  
10  
11  
12  
13  
14  
15  
16  
17  
18  
19  
20  
54  
55  
56  
57  
58  
59  
60

21  
22  
23  
24  
25  
26  
27  
28  
29  
30  
31  
32  
33  
34  
35  
36  
37  
38  
39  
40  
41  
42  
43  
44  
45  
46  
47  
48  
49  
50  
51  
52  
53



1  
2  
3  
4  
5  
6  
7  
8

# Veterinary Record casereports

1  
2  
3  
4  
5  
6  
7

## Submission template for full cases

9

All case reports MUST be submitted online using this Word template. Please refer to the [template](#) so you know what to include in each section [Hints and Tips](#)

10

o <http://mc.manuscriptcentral.com/vetreccr>

12

o You will be asked for more detailed information on submission where you can also upload 14 images, multimedia files, etc 15 o Further details are available in the [Instructions for authors](#) 16 17 For studies using client-owned animals the article must demonstrate a high standard (best practice) of 18 veterinary care and have informed client consent

13  
14  
15  
16  
17  
18  
19

You, your practice or institution must be a subscriber to Veterinary Record Case Reports in order to 21 submit. Subscribers can submit as many cases as they like, access all the published material, and re-use 22 any published material for personal use and teaching without further permission.

20

o For more information on rates and how to purchase your subscription visit

23

<http://vetrecordcasereports.bmj.com/site/about/Subslanding.xhtml>

24

o Contact your librarian, head of department or practice owner to see if your institution already has a subscription

25

26  
27

<b>TITLE OF CASE <i>Do not include "a case report"</i></b>
POSTOBSTRUCTIVE NEGATIVE PRESSURE PULMONARY OEDEMA IN A DOG
<b>SUMMARY <i>Up to 150 words summarising the case presentation and outcome (this will be freely available online)</i></b>

54  
55  
56  
57  
58  
59  
60

A four-month-old English bulldog was anaesthetised for investigation and management of chronic urinary incontinence. In the post-anaesthetic period the patient developed respiratory distress, with marked cough and increased inspiratory effort. Diagnostic imaging suggested pulmonary oedema. After excluding all other causes of cardiogenic and non-cardiogenic pulmonary oedema it was hypothesised that the patient developed postanaesthetic negative pressure pulmonary oedema, suspected to have been exacerbated by tracheal intubation with an oversized endotracheal tube leading to laryngeal swelling and obstruction. The animal was treated with oxygen supplementation, corticosteroids and  $\beta$ -2 adrenergic receptor agonists. The patient recovered from the event and was discharged from the hospital after forty-eight hours. This article discusses in further details other management options of negative pressure pulmonary oedema. This is the first case report discussing the pathophysiology, critical care and management of post-anaesthetic negative pressure pulmonary oedema in a dog.

**BACKGROUND** *Why you think this case is important – why did you write it up?*

1  
2  
3  
4  
5  
6  
7  
8

Pulmonary oedema is defined as an abnormal accumulation of fluid in the extravascular tissues and spaces of the lung that occurs when the lymphatic circulation is unable to drain the excessive fluid present in the extravascular space <sup>1</sup>.

Post-obstructive pulmonary oedema can be subdivided into two types: Type 1 ~~which~~ is associated with an increase in inspiratory effort due to an acute upper airway obstruction (UAO) and type 2 ~~which~~ results from ~~a the~~ relief of a chronic partial UAO (e.g. after laryngeal mass resection) <sup>2</sup>. Post-obstructive pulmonary oedema type 1 is also known as negative pressure pulmonary oedema (NPPO) and has been highlighted as a potential complication in the ~~post-anaesthetic~~ period in people and horses<sup>3,4</sup>. Multiple causes have been attributed to the development of NPPO: brachycephalic obstructive airway syndrome (BOAS), strangulation, choking, near drowning, airway collapse, laryngeal mass, laryngeal paralysis, endotracheal tube (ETT) obstruction, laryngospasm and partial occlusion of the upper airway tract with a foreign body or other mass <sup>2,5</sup>.

~~The pathophysiologic mechanism behind NPPO was primarily described in the 1940s <sup>6</sup> and it is now accepted that this is a multifactorial process involving negative pressures and hypoxia<sup>2</sup>.~~

~~Physiologically the UAO creates a large negative transpulmonary and interpleural pressure gradient favouring movement of fluid from the capillaries ~~through the alveolar capillary barrier~~ into the extravascular space <sup>3</sup>. ~~This increase in hydrostatic pressures and oedema formation in the lungs <sup>2,7</sup>, contributes to the leading to lung tissue oedema and the~~ overall translocation of fluid ~~from the capillaries~~ into the alveolar spaces.~~

In the veterinary literature few reports have been published discussing this event. In 1927, a research article reporting the response to respiratory resistance in dogs found that a partial fixed obstruction during a prolonged inspiratory phase resulted in lesions compatible with pulmonary oedema at post-mortem examination <sup>8</sup>. In 1989 and 1995, two case series described the development of pulmonary oedema in conscious dogs due to UAO resulting from laryngeal

**Commented [CA3]:** Please choose the English or the American spelling for words and stick to it for the rest of the manuscript

**Commented [CA4]:** I do not think that the UAO creates the pressure gradient but rather the inspiratory effort against the UAO?

**Commented [CA5]:** What about the role of hypoxia then? Generation of mediators? Bronchoconstriction? Neurogenic exacerbation of breathing work?

**Commented [CA6]:** Maybe keep this paragraph for the discussion

54  
55  
56  
57  
58  
59  
60

9 paralysis, laryngeal oedema or obstructive airway masses <sup>9,10</sup>. Another case series was recently  
10 published describing the radiographic appearance of 23 cases with presumed post-obstructive  
11 pulmonary oedema in conscious dogs <sup>5</sup>.

12  
13 To the authors knowledge this is the first case report in the veterinary literature describing the  
14 pathophysiology, critical care and management of post-anaesthetic NPPO in a dog.  
15  
16  
17  
18  
19  
20  
21  
22  
23  
24  
25  
26  
27  
28  
29  
30  
31  
32  
33  
34  
35  
36  
37  
38  
39  
40  
41  
42  
43  
44  
45  
46  
47  
48  
49  
50  
51  
52  
53

Commented [CA7]: Diagnosis ?


**CASE PRESENTATION *Presenting features, clinical and environmental history***

A four-month-old, 11.6 kg, body condition score 6/9 <sup>11</sup>, female English Bulldog was presented for investigation and management of chronic urinary incontinence of one-month duration. At presentation the patient was bright and alert. Clinical examination revealed a recessed vulva and

Revised August 2017

- 1
- 2
- 3
- 4
- 5
- 6
- 7
- 8

- 54
- 55
- 56
- 57
- 58
- 59
- 60





urine-stained fur in the peri-vulvar area. Thoracic auscultation was unremarkable, respiratory rate was 32 rpm and no obvious BOAS was detected. Cardiac auscultation was unremarkable (no murmurs detected) and the heart rate was 140 bpm with regular rhythm. Temperature recorded was 38°C. Blood haematology and serum biochemistry were unremarkable. An American Society of Anaesthesiology (ASA) physical status classification of 2 was assigned to the dog<sup>12</sup>. A Computed Tomography (CT) scan of the thorax and abdomen, under sedation, was scheduled for the same day. The patient was premedicated with 0.01mg/kg medetomidine (Medetor, Virbac) and 0.2mg/kg butorphanol (Dolorex, MSD Animal Health) by intramuscular injection. A 22 gauge intravenous cannula was placed aseptically in the left cephalic vein. Oxygen was supplemented via face mask throughout the sedation period at a flow rate of 4L/min. Fluid therapy was initiated, before CT contrast was administered, with Hartmann's Solution (Aquapharm 11, Animacare) at a rate of 4mL/kg/hr. Pulse oximetry, non-invasive oscillometric blood pressure measurement, pulse rate and respiratory rate were monitored using a multiparameter monitor (Datex-Ohmeda S/5, GE Healthcare).

CT examination of the abdomen following intravenous injection of contrast medium revealed dilation of the urethra with absence of normal vesiculourethral junction and mild dilation of the left ureter.

A retrograde vaginourethrogram was ~~immediately~~ performed under general anaesthesia, immediately after the CT scan. Propofol 2mg/kg (PropoFlo Plus, Zoetis) was administered intravenously. The trachea was intubated using a cuffed (high volume, low pressure) 8 mm inner diameter polyvinyl chloride (PVC) ETT. No difficulties were encountered during tracheal intubation although the ETT was found to be close-fitting as no cuff inflation was required when leak testing the system. General anaesthesia was maintained with sevoflurane (SevoFlo, Zoetis) vaporised in 100 per cent oxygen. Anaesthetic monitoring included electrocardiography, pulse oximetry, capnography and noninvasive oscillometric blood pressure measurement using a multiparameter monitor (DatexOhmeda S/5, GE Healthcare). The trachea was extubated as soon as the patient swallowed, no complications were detected at that time, and no fluid or foam were visualised in the ETT. There were no breathing difficulties or signs of gastroesophageal reflux (GOR) detected after extubation. The patient was hypothermic in the recovery period (35.9°C). In order to treat the hypothermia active warming was initiated with an active warming device (Hot Dog Patient Warming; Augustine Surgical Inc) and further temperature measurements were performed until the hypothermia resolved three hours after extubation. The patient was kept on intravenous fluid therapy for fifteen hours at a rate of 4ml/kg/hr, using a fluid pump, in order to avoid CT contrast induced nephropathy<sup>13</sup>. Fluid therapy guidelines suggest maintenance fluid rates between 2-6 ml/kg/hr in healthy dogs<sup>14</sup>. Well-hydrated patients with normal renal and heart function are generally able to regulate and excrete this fluid volumes. Although unlikely, this fluid therapy

**Commented [CA8]:** Was this scheduled initially ? What was the indication based on the dog's initial problem?

**Commented [CA9]:** sedated

**Commented [CA10]:** Iodinated contrast agent

**Commented [CA11]:** Described

**Commented [CA12]:** Can be deleted

**Commented [CA13]:** This should be in the differential diagnosis and/or the discussion

1  
2  
3  
4  
5  
6  
7  
8  
9  
10  
11  
12  
13  
14  
15  
16  
17  
18  
19  
20  
21  
22  
23  
24  
25  
26  
27  
28  
29  
30  
31  
32  
33  
34  
35  
36  
37  
38  
39  
40  
41  
42  
43  
44  
45  
46  
47  
48  
49  
50  
51  
52  
53

regime may have predisposed the patient to volume overload.

The animal was hospitalised overnight and was examined every four hours. The patient was considered clinically normal for the last time at 4am. At 8 am, fourteen hours after general anaesthesia, clinical examination of the patient revealed coughing, respiratory distress with a marked increase in inspiratory effort and a respiratory rate of 40 rpm. During thoracic auscultation increased upper respiratory sounds and wheezes were heard ~~and~~. No crackles were noticed. On cardiac auscultation, no heart murmur was heard, the patient had a regular heart rhythm, the heart rate was 124 bpm, mucous membranes were pink and moist, and the capillary refill time was one second. Rectal temperature measured was 38,7°C. Urgent thoracic radiographs were performed to establish the origin of the sudden onset of respiratory distress. The possibility of regurgitation followed by aspiration and subsequent pneumonia was suspected.

Commented [CA14]: Should be in investigations

**INVESTIGATIONS *If relevant***

54  
55  
56  
57  
58  
59  
60

9  
10  
11  
12 In order to perform radiographs, the patient was sedated with 0.001mg/kg medetomidine (Medetor,  
13 Virbac) and 0.2mg/kg butorphanol (Dolorex, MSD Animal Health) intravenously. Dorsoventral  
14 and lateral inspiratory thoracic radiographs were obtained (Fig.1). A generalised increase in soft  
15 tissue and ground glass opacities of the pulmonary parenchyma was identified, associated with  
16 multiple air bronchograms (unstructured interstitial and alveolar lung patterns). The pulmonary  
17 lesions were more severe in the perihilar region and reduced in severity towards the periphery. The  
18 border of the cardiac silhouette was partially effaced by the neighbouring lung changes, but the  
19 cardiac silhouette was not enlarged. Retrospectively, the CT of the caudal thorax earlier performed  
20 revealed no abnormalities in the caudal two thirds of the lungs. Tracheal inner diameter measured  
21 8.92mm and thoracic inlet measurement 6.67cm. The tracheal:- thoracic inlet ratio was within  
22 normal limits for a English Bulldog (~~0.134~~)<sup>15,16</sup>.  
23  
24  
25  
26  
27  
28

29 Due to the more severe pulmonary lesions in the perihilar region suggesting the possibility of  
30 cardiogenic pulmonary oedema, a single dose of furosemide at 2mg/kg was administered  
31 intravenously promptly and an echocardiography was performed. Neither left nor right atrial  
32 enlargement was identified and systolic function appeared normal. There were no valvular  
33 regurgitations and no evidence of increased filling pressures detected; therefore, cardiogenic cause  
34 of pulmonary oedema was discarded.  
35  
36  
37  
38

39 The pharynx and the larynx were visually examined using ~~a laryngoscope with a light source~~  
40 ~~with~~while the animal ~~was~~ profoundly sedated. The larynx was ~~found to be~~ grossly inflamed with  
41 erythema and swelling of the area. No mass, foreign body, laryngeal paralysis or other source of  
42 UAO was  
43  
44  
45  
46  
47  
48  
49  
50  
51  
52  
53

1  
2  
3  
4  
5  
6  
7  
8  
9  
10  
11  
12  
13  
14  
15  
16  
17  
18  
19  
20  
21  
22  
23  
24  
25  
26  
27  
28  
29  
30  
31  
32  
33  
34  
35  
36  
37  
38  
39  
40  
41  
42  
43  
44  
45  
46  
47  
48  
49  
50  
51  
52  
53  
54  
55  
56  
57  
58  
59  
60

identified during examination.

---

**DIFFERENTIAL DIAGNOSIS *If relevant***

From the history, presentation and radiographic findings a non-cardiogenic pulmonary oedema was highly suspected. Alternative differential diagnoses included idiopathic interstitial pneumonia, neoplastic infiltration or non-witnessed aspiration pneumonia.


A presumptive diagnosis of post-anaesthetic NPPO was made.

**Commented [CA15]:** Maybe this ddx needs to be mentioned first as it is the one you originally treated for and that you are discussing first later

Veterinary Record Case Reports

39  
40  
41  
42  
43  
44  
45  
46  
47  
48  
49  
50  
51  
52  
53  
54  
55  
56  
57  
58  
59  
60

**TREATMENT** *If relevant*



1  
2  
3  
4  
5  
6  
7  
8

The dog was transferred to the intensive care unit. The patient showed laboured breathing and a significant stertor could be heard. Positioning the patient with the neck extended significantly improved ~~the her~~ level of comfort. A continuous rate infusion of butorphanol (Dolorex; MSD Animal Health) at 0.2mg/kg/hr was started to provide sedation, analgesia and antitussive therapy with minimal respiratory depression <sup>17,18</sup>. Oxygen supplementation via nasal prongs was implemented at a flow rate of 1.5L min<sup>-1</sup>. Saturation of haemoglobin with oxygen was monitored using a portable pulse oximeter (Radical 7 Pulse Oximeter; Masimo). No episodes of ~~patient's~~ desaturation were reported, ~~pulse oximeter oxygen haemoglobin saturation~~ values were always above 95% of saturation of haemoglobin with oxygen.

Salbutamol nebulization therapy (Ventolin: Glaxo Smith Klein) was initiated at a dose of 0.035 mg/kg ~~TID~~ administered via metered dose inhalers over periods of 6 breaths using an aerosol chamber with a fitted face mask (AeroDawg; Truddel Medical International).

Therapy with dexamethasone (0.2mg/kg IV SID) (Colvasone, Norbook); omeprazole (1mg/kg IV BID) (Omeprazole; Star Pharmaceuticals Ltd.); and cefuroxime (20mg/kg IV TID) (Zinacef; GlaxoSmithKlein) was initiated due to the possibility of regurgitation followed by aspiration and subsequent pneumonia ~~as a potential differential diagnosis at the time~~.

**OUTCOME AND FOLLOW-UP**

**Commented [CA16]:** Is this a higher dose than usually recommended? Deliberate choice or dictated by the inhaler?

**Commented [CA17]:** Acronym ?

54  
55  
56  
57  
58  
59  
60

Veterinary Record Case Reports

The animal responded well to treatment. Sixteen hours after the initial clinical signs, the patient was bright and alert. Respiratory rate decreased (20 rpm), no cough or increased inspiratory effort was detected. All medications were discontinued 36 hours after recognition of the clinical signs.

The animal was discharged from the hospital 48 hours after this event. Unfortunately, no follow up imaging was performed.

Six months after discharge the animal has fully recovered from this episode with no complications arising from the NPPO.

**DISCUSSION** *Include a very brief review of similar published cases*

**DIFFERENTIAL DIAGNOSIS**

The possibility of aspiration and secondary pneumonia was initially suspected before diagnostic imaging was performed. In anaesthetised dogs, gastric oesophageal reflux (GOR) has a high

Commented [CA18]: delete

1  
2  
3  
4  
5  
6  
7  
8

incidence, which ranges from 16 per cent<sup>19</sup> to 55 per cent<sup>20</sup>. A clinical trial showed a higher incidence of GOR (60 per cent vs 40 per cent) when comparing anaesthetised brachycephalic and non-brachycephalic dogs, although ~~this the difference~~ was not statistically significant<sup>21</sup>. This is, in part, related to the high negative intrathoracic pressures generated to overcome the upper respiratory tract obstruction <sup>22-24</sup>. GOR is associated with an increased risk of aspiration and secondary pneumonia

<sup>22,24</sup>.

In ~~this case~~ the case reported here and with hindsight, we ~~can exclude~~ excluded the possibility of aspiration pneumonia as the cause of the pulmonary oedema due to the rapid resolution of the clinical signs. Two studies reflected on the duration of hospitalization-hospitalisation for dogs with aspiration pneumonia and resolution of clinical signs. Results showed in these studies ranged from 3 to 5 days of hospitalization in the intensive care unit for dogs recovering from aspiration pneumonia <sup>25,26</sup>.

**Commented [CA19]:** Two studies investigated this question and showed that..

~~In terms of radiography~~ Moreover, there are different radiographic appearances when comparing NPPO to aspiration pneumonia. In aspiration pneumonia the most gravity dependent areas are the most frequently affected<sup>27</sup>. ~~The positioning of the patient during aspiration may predict the location of pulmonary infiltrates.~~ In sternal recumbency it is more likely that the right lung is affected, as the right mainstem bronchus is a more direct prolongation of the trachea than the left. In ventrodorsal positioning the caudal lung lobes seem to be more affected <sup>28</sup>. A recent case series focused on the radiographic appearance of non-cardiogenic pulmonary oedema suggested that a dorsal distribution of the lung lesions seemed to be more often observed in NPPO than in other causes of non-cardiogenic pulmonary oedema, although, the authors could not give an explanation

**Commented [CA20]:** dorsal recumbency

54  
55  
56  
57  
58  
59  
60



1  
2  
3  
4  
5  
6  
7  
8  
9  
10  
11  
12  
13  
14  
15  
16  
17  
18  
19  
20  
21  
22  
23  
24  
25  
26  
27  
28  
29  
30  
31  
32  
33  
34  
35  
36  
37  
38  
39  
40  
41  
42  
43  
44  
45  
46  
47  
48  
49  
50  
51  
52  
53  
54  
55  
56

to this finding<sup>5</sup>.

In dogs with experimentally induced lung aspiration, radiographic signs were only seen 24 hours post aspiration and clinical signs of cough and respiratory distress were only present two days after the event<sup>28</sup>. In this case, clinical signs and radiographic changes occurred between ten to fourteen hours after extubation, ~~although aspiration before sedation cannot be excluded~~. Also, abnormal radiographic findings ~~were mainly caudodorsally located which~~ differs from cases of aspiration pneumonia.


In human medicine, ~~this~~ post-anaesthetic ~~complication~~ NPPO has a variable onset of clinical signs, ~~it may~~ which may vary from few minutes to several hours (up to 24 hours) following extubation or relief of obstruction<sup>2,29,30</sup>. Delayed onset of laryngeal oedema due to trauma has been reported as a complication of the surgical treatment of BOAS in dogs<sup>31</sup>. In one case series, four dogs developed laryngeal oedema post-surgery. The onset of clinical signs of upper airway obstruction, such as increased respiratory effort and cyanosis, were noted one, three, seven and ten hours after surgery. The authors mentioned that the laryngeal oedema could have resulted from surgery trauma or induced by the ETT<sup>31</sup>.

**Commented [CA21]:** different description compared to the Investigation paragraph

**Commented [CA22]:** Why does this help your discussion about differential diagnosis?

1  
2  
3  
4  
5  
6  
7  
8  
57  
58  
59  
60

54  
55  
56  
57  
58  
59  
60



Other causes of non-cardiogenic pulmonary oedema, such as direct lung injury (fire smoke exposure, toxin inhalation); neurogenic oedema (electrocution); systemic disease (neoplasia, uremic syndrome, pancreatitis); near drowning; blood transfusion; anaphylaxis<sup>5</sup> were also discarded by clinical history, clinical examination and blood analysis. Neurogenic oedema due to seizures is difficult to completely exclude as the animal was not constantly monitored overnight and a seizure episode cannot be completely excluded. Although, to date, no history or clinical signs of neurologic disease have been reported in this patient, therefore the main causes of neurogenic pulmonary oedema were considered unlikely.

#### CONTRIBUTION FACTORS FOR THE DEVELOPMENT OF NPPO PATHOPHYSIOLOGY

It is believe that the animal described here suffered from type 1 post-obstructive pulmonary oedema, due to a suspected upper airway obstruction caused by gross swelling and erythema of the larynx. This may have been exacerbated from suspected trauma during tracheal intubation with an oversized ETT. A recent study in Beagles suggested that a suitably sized ETT for dogs should measure 70% of the internal tracheal diameter measured on thoracic radiography<sup>32</sup>. In this particular case, the measurement using the same method revealed 8.92mm internal tracheal diameter which corresponds to a 6.2mm ETT. An 8mm ETT was used to intubate the trachea of this patient, which could potentially explain the laryngeal swelling, erythema and secondary post extubation UAO.

#### BOAS

~~BOAS has an impact on the management of these patients during anaesthesia and recovery~~<sup>22</sup>. BOAS is characterised by dynamic and/or static UAO<sup>33</sup>. ~~These patients suffering from this syndrome~~ are subjected to an increased resistance to inspiratory airflow which results in increased inspiratory effort and the generation of supraphysiologic negative thoracic and airway pressures<sup>33</sup>. In severe cases of BOAS, UAO can result in NPPO<sup>22</sup>. In our patient brachycephalic conformation may have played a role in aggravating the UAO.

#### SEDATION

~~This animal was sedated with a low dosage of medetomidine to safely perform the radiographs and the echocardiography.~~ In cases of NPPO,  $\alpha_2$ -agonists must be used with caution. Profound sedation with this class of drugs induces recumbency, reduces pharyngeal muscle tone and may predispose to hypoventilation. All of these factors can theoretically worsen any UAO already present<sup>22,34</sup>. On the other hand, sedation may be useful in controlling excessive panting associated with stress, reducing further airway swelling or collapse and decreasing oxygen consumption<sup>23</sup>. ~~This animal was sedated with a low dosage of medetomidine to safely perform the radiographs and the echocardiography.~~ This patient was closely monitored for signs of UAO including increased stertor/stridor, increased inspiratory effort and exaggerated movement of the chest wall.

Commented [CA23]: I like this formulation very much.

Commented [CA24]: It could be interesting to mention the external diameter of an 8 mm ETT instead. (so that the reader can have an idea of the importance of this factor in the possible trauma inflicted)

Commented [CA25]: Should this be  $\alpha_2$ -adrenergic agonist? Same comments for other sympathomimetic drugs

Commented [CA26]: This is a review article. Try to find primary source of information if available

1  
2  
3  
4  
5  
6  
7  
8

Elevating the patient’s head improved the audible stertor/stridor during sedation. Oxygen was supplemented via face mask and haemoglobin saturation with oxygen was monitored via pulse oximetry at all times during this process. ~~If necessary atipamezole could have been administered in this case, as this  $\alpha_2$ -antagonist counteracts the respiratory depression caused by the administration of  $\alpha_2$ -agonists~~<sup>35,36</sup>. Butorphanol can be used to provide sedation, analgesia and antitussive therapy with minimal respiratory depression in cases of respiratory distress and was used successfully<sup>17,18</sup>.

**Commented [CA27]:** atipamezole

PAEDIATRIC PATIENT

~~The fact that this was a paediatric patient may have played a role in the development of pulmonary oedema in this case.~~ Young animals have a smaller functional residual capacity, therefore they will quickly develop hypoxia in the event of an UAO<sup>37,38</sup>. The rib cage of young animals is very compliant, resulting in less competent ventilation and greater work of breathing. This may predispose paediatric patients to hypoxia and ventilatory fatigue, which can be aggravated in the event of an UAO<sup>38</sup>. The larynx of puppies is delicate, and extreme care should be taken to intubate the trachea atraumatically<sup>37</sup>. This patient was 4 months old and intubation of the trachea was performed with an oversized ETT which potentially caused the laryngeal oedema, which was theorised to be the cause of the UAO. ~~Hypoxia may have developed quicker in this patient for the reasons described above.~~

**Commented [CA28]:** The physiology of young individuals put them at a higher risk of developing pulmonary oedema and hypoxia in case of UAO.

TREATMENT

The priorities in patients presenting NPPO are to relieve the UAO and correct the hypoxaemia. Supportive care should be implemented ~~aiming~~ to maintain a patent airway and ~~ensuring~~ ensure adequate oxygenation<sup>2,39</sup>. Oxygen supplementation, continuous positive airway pressure (CPAP), intermittent positive pressure ventilation (IPPV) and positive end-expiratory pressure (PEEP) are methods ~~used~~ described to fulfil those goals. Other medications such as glucocorticoids and  $\beta_2$ -

54  
55  
56  
57  
58  
59  
60

agonists are also used to ~~minimize~~ ~~minimise~~ the ~~impact of the~~ UAO.

#### OXYGEN SUPPLEMENTATION

Traditional oxygen therapy is most usually provided via a face mask, nasal prongs or oxygen cage, delivering dry, cold oxygen with FIO<sub>2</sub> of 40 to 70% at flow rates of 50–150 mL/kg/min<sup>40</sup>. In a research project including twenty healthy dogs, the mean partial pressure of oxygen (PaO<sub>2</sub>) in arterial samples taken after face mask oxygen supplementation was 371.3 mmHg compared to the control group composed by dogs breathing room air (82.43 mmHg)<sup>40</sup>. Passive oxygen administration via a nasal prongs was chosen in this case to provide oxygen to the patient. Unfortunately, no arterial blood gas analysis was performed; this could have provided more reliable information regarding the haemoglobin saturation with oxygen and PaO<sub>2</sub>.


#### CPAP

CPAP is a mode of ventilation used in spontaneously breathing subjects. This is used in humans

Commented [CA29]: is this relevant to the case?

1  
2  
3  
4  
5  
6  
7  
8  
57  
58  
59  
60

54  
55  
56  
57  
58  
59  
60



for the treatment of NPPO and sleep apnoea<sup>2,41</sup>. The objective of CPAP is to maintain a positive pressure in the airways during inspiration and expiration. ~~This-The~~ intrathoracic positive pressure ~~at the end of expiration will improve~~s alveolar ventilation and re-expand flooded alveoli, promoting the fluid to return to the interstitial space<sup>42</sup>. Other benefits of CPAP include a reduction in preload due to an increase in intrathoracic pressure and a reduction in afterload, via an increase in pericardial pressure and reduction in transmural pressure<sup>42</sup>. It also improves oxygenation, gas exchange, vital signs and reduces work of breathing<sup>43,44</sup>. One of the advantages of CPAP delivery is that there is no need for tracheal intubation and mechanical ventilation. No CPAP delivering devices ~~have has~~ been specifically designed for veterinary patients. Two human interfaces for CPAP delivery have been studied in dogs,<sup>45,46</sup>. In healthy sedated dogs, when comparing CPAP via face mask with traditional oxygen therapy delivered via regular face mask, CPAP increased PaO<sub>2</sub> by 102 mmHg and was well tolerated by the patients<sup>45</sup>. ~~Some D~~disadvantages have been highlighted in a research project testing three methods of non-invasive CPAP delivery (custom-made mask, conical face mask and helmet): significant leaks were found when CPAP was delivered to sedated dogs. There is a significant risk of rebreathing and hypoxaemia when CPAP was not maintained. The authors concluded that animals should always be supervised during administration of CPAP<sup>47</sup>. In our patient this method of ventilation was not used because it was not available. ~~at the time, in our opinion it would have been a valid option for treatment of this patient because it would maintain a patent airway, improved oxygenation and reduced the work of breathing. Nevertheless, the temperament of the animal could have limited the use of CPAP in this case.~~

IPPV

IPPV with PEEP has been used in veterinary medicine for treatment of non-cardiogenic pulmonary oedema<sup>48</sup>. The application of PEEP counterbalances the hydrostatic forces leading to pulmonary oedema, redistributing the extravascular fluid from the alveoli into perivascular interstitium and maintaining airway patency<sup>49</sup>. PEEP also improves gas exchange and recruits alveolar units. Application of PEEP up to 13 cmH<sub>2</sub>O improved alveolar gas exchange in experimentally induced canine pulmonary oedema<sup>50,51</sup>. In this case IPPV and PEEP were not used because this would require endotracheal intubation which could have perpetuated the laryngeal inflammation already present. In human patients with NPPO, IPPV and PEEP are only implemented in severe cases of hypoxaemia, ventilation/perfusion mismatch and poor lung compliance<sup>2</sup>. IPPV and PEEP may present disadvantages when compared to other methods of ventilation such as CPAP. These included: an increased risk of morbidity and mortality; the development of pneumonia, volutrauma and barotrauma; requirements for expensive and specialised equipment and staff; higher costs of patient management in an ICU setting<sup>45,52</sup>.

FUROSEMIDE


In patients suffering from fluid overload, diuretics may play a part in the resolution of pulmonary

Commented [CA30]: Evidence in dogs ?

Commented [CA31]: What about tracheostomy?

- 1
- 2
- 3
- 4
- 5
- 6
- 7
- 8

- 54
- 55
- 56
- 57
- 58
- 59
- 60





Veterinary Record Case Reports

oedema, but in other cases ~~their role~~its indication remains uncertain<sup>53,54</sup>. ~~The reasoning behind using diuretics in these cases is~~Diuretics can be administered ~~to~~ in an attempt to decrease the intravascular volume and alter Starling's equation in favour of intra-capillary filtration and oedema resolution<sup>30</sup>. ~~In our patient~~ Furosemide was administered after radiographs confirmed pulmonary oedema. We had a concern that our patient may have been fluid overloaded, as she received fluid therapy at a rate of 4ml/kg/hr for a period of fifteen hours. The echocardiography discarded that possibility as well as cardiogenic pulmonary oedema.

Therefore the use of furosemide could have been avoided in this particular case.

#### CORTICOSTEROIDS

Upper airway inflammation is associated with airway narrowing and obstruction. This increases airway resistance, may perpetuate inflammation and worsen coughing episodes. In the ~~short term~~short-term glucocorticoids may be useful in animals with BOAS with pharyngeal or laryngeal swelling<sup>55</sup>. ~~Glucocorticoids were~~Dexamethasone was used in ~~this our~~ case after examination of the larynx, to decrease the inflammation detected in that area.

#### SALBUTAMOL

~~$\beta_2$ -agonists may be useful in lower airway disease in dogs<sup>55</sup> – The use of  $\beta_2$ -agonists is current practice in the treatment of NPPO in human medicine<sup>59</sup>~~In human medicine, aerosolized salbutamol was found to accelerate the resolution of pulmonary oedema, improve blood oxygenation, and stimulate cardiovascular function after lung lobe resection<sup>56</sup>.  $\beta_2$ -agonists could potentially increase the rate of alveolar fluid clearance through increased active cation transport, which may well accelerate the resolution of the clinical signs of pulmonary oedema<sup>57,58</sup>. ~~The use of  $\beta_2$ -agonists is current practice in the treatment of NPPO in human medicine<sup>59</sup>~~. Furthermore Interstitial oedema may induce narrowing of the bronchial lumen. This can be detected on thoracic auscultation as wheezing sounds<sup>57</sup>. In our case, clear wheezing was detected on thoracic auscultation; therefore, ~~nebulisation bronchodilation~~ with salbutamol was initiated.

#### LEARNING POINTS/TAKE HOME MESSAGES **3 to 5 bullet points – this is a required field**

- Endotracheal intubation should be performed atraumatically with an appropriately sized ETT (in length and diameter). When intubating the trachea of a patient correct position of the patient, use of laryngoscope (which provides adequate light and ~~visualization~~visualisation of the larynx) and appropriate depth of anaesthesia are extremely important to avoid complications.
- Delayed onset of laryngeal oedema resulting in NPPO is possible; therefore animals should be closely monitored in the post-operative period.
- NPPO ~~is a potential complication in the pre-anaesthetic period and~~ can be treated with oxygen supplementation, corticosteroids and short-acting  $\beta_2$ -agonists.

Commented [CA32]: reference

Commented [CA33]: Some authors...

Commented [CA34]: If this is common use for treatment of NPPO, maybe move this paragraph after oxygenation techniques


Commented [CA35]: Consider the order of take-home messages by order of importance ?

Commented [CA36]: post

Commented [CA37]: only if laryngeal swelling or all NPPO ?

1  
2  
3  
4  
5  
6  
7  
8  
57  
58  
59  
60

54  
55  
56  
57  
58  
59  
60



Page 26 of 33  Early recognition of the clinical signs and establishment of a prompt diagnosis is extremely important in the outcome of the case.

**REFERENCES Vancouver style**

- 1 West JB. Pulmonary Edema. In: *Pulmonary physiology and pathophysiology : an integrated, case-based approach*. Wolters Kluwer Health/Lippincott Williams & Wilkins, 2007, pp 94–104.
- 2 Udeshi A, Cantie SM, Pierre E. Postobstructive pulmonary edema. *J Crit Care* 2010; **25**: 508.e1–508.e5.
- 3 Lorch G, Sahn A. Post-Extubation Pulmonary Edema Following Anesthesia Induced by Upper Airway Obstruction: Are Certain Patients at Increased Risk? *Chest* 1986; **90**: 802–805.
- 4 Senior M. Post-anaesthetic pulmonary oedema in horses: A review. *Vet Anaesth Analg* 2005; **32**: 193–200.
- 5 Bouyssou S, Specchi S, Desquilbet L, Pey P. Radiographic Appearance of Presumed Noncardiogenic Pulmonary Edema and Correlation With the Underlying Cause in Dogs and Cats. *Vet Radiol Ultrasound* 2017; **58**: 259–265.
- 6 Warren MF, Peterson DK, Drinker CK. The effects of heightened negative pressure in the chest, together with further experiments upon anoxia in increasing the flow of lung lymph. *Am J Physiol Content* 1942; **137**: 641–648.
- 7 Guffin TN, Har-El G, Sanders A, Lucente FE, Nash M, York N. Acute postobstructive pulmonary edema. *Otolaryngol - Head Neck Surg* 1995; **112**: 235–237.
- 8 Moore RL, Binger CA. the Response To Respiratory Resistance : a Comparison of the Effects Produced By Partial Obstruction in the Inspiratory and Expiratory Phases of Respiration. *J Exp Med* 1927; **45**: 1065–80.
- 9 Drobatz KJ, Saunders HM, Pugh CR, Hendricks JC. Noncardiogenic pulmonary edema in dogs and cats: 26 cases (1987-1993). *J Am Vet Med Assoc* 1995; **206**: 1732–6.
- 10 Kerr LY. Pulmonary edema secondary to upper airway obstruction in the dog: a review of nine cases. *J Am Anim Hosp Assoc* 1989; **25**: 207–212.
- 11 Laflamme DP. Development and validation of a body condition score system for dogs. *Canine Pract* 1997; **22**: 10–15.
- 12 American Society of Anesthesiologists. American Society of Anesthesiologists: ASA Physical Status Classification System. *Am. Soc. Anesthesiol.* 2014; : 1–2.

1  
2  
57  
58  
59  
60

- 13 Wong GTC, Irwin MG. Contrast-induced nephropathy. *Br J Anaesth* 2007; **99**: 474–83.
- 14 Davis H, Jensen T, Johnson A, Knowles P, Meyer R, Rucinsky R *et al*. AAHA/AAFP Fluid Therapy Guidelines for Dogs and Cats\*. *J Am Anim Hosp Assoc* 2013; **49**: 149–159.
- 15 Harvey CE, Fink EA. Tracheal diameter: analysis of radiographic measurements in brachycephalic and nonbrachycephalic dogs. *J Am Anim Hosp Assoc* 1982; **18**: 570–576.
- 16 Ingman J, Näslund V, Hansson K. Comparison between tracheal ratio methods used by three observers at three occasions in English Bulldogs. *Acta Vet Scand* 2014; **56**: 79.
- 17 Dyson DH. Update on butorphanol tartrate: use in small animals. *Can Vet J* 1990; **31**: 120–121.
- 18 Cavanagh RL, Gyls JA, Bierwagen ME. Antitussive properties of butorphanol. *Arch Int Pharmacodyn Ther* 1976; **220**: 258–68.
- 19 Galatos AD, Raptopoulos D. Gastro-oesophageal reflux during anaesthesia in the dog: the effect of age, positioning and type of surgical procedure. *Vet Rec* 1995; **137**: 513–6.
- 20 Wilson D V, Evans AT, Miller R. Effects of preanesthetic administration of morphine on gastroesophageal reflux and regurgitation during anesthesia in dogs. *Am J Vet Res* 2005; **66**: 386–90.
- 21 Shaver SL, Barbur LA, Jimenez DA, Brainard BM, Cornell KK, Radlinsky MG *et al*. Evaluation of Gastroesophageal Reflux in Anesthetized Dogs with Brachycephalic Syndrome. *J Am Anim Hosp Assoc*; **53**: 24–31.

54  
55  
56  
57  
58  
59  
60

Veterinary Record Case Reports

- 22 Downing F, Gibson S. Anaesthesia of brachycephalic dogs. *J Small Anim Pract* 2018; **59**: 725–733.
- 23 Boesch RP, Shah P, Vaynblat M, Marcus M, Pagala M, Narwal S *et al.* Relationship between upper airway obstruction and gastroesophageal reflux in a dog model. *J Investig Surg* 2005; **18**: 241–245.
- 24 Shaver SL, Barbur LA, Jimenez DA, Brainard BM, Cornell KK, Radlinsky MG *et al.* Evaluation of Gastroesophageal Reflux in Anesthetized Dogs with Brachycephalic Syndrome. *J Am Anim Hosp Assoc* 2017; **53**: 24–31.
- 25 Kogan DA, Johnson LR, Sturges BK, Jandrey KE, Pollard RE. Etiology and clinical outcome in dogs with aspiration pneumonia: 88 cases (2004–2006). *J Am Vet Med Assoc* 2008; **233**: 1748–1755.
- 26 Tart KM, Babski DM, Lee JA. Potential risks, prognostic indicators, and diagnostic and treatment modalities affecting survival in dogs with presumptive aspiration pneumonia: 125 cases (2005–2008). *J Vet Emerg Crit Care* 2010; **20**: 319–329.
- 27 Sherman R, Karagiannis M. Aspiration Pneumonia in the Dog: A Review. *Top Companion*

1  
2  
57  
58  
59  
60

*Anim Med* 2017; **32**: 1–7.

- 28 Eom K, Seong Y, Park H, Choe N, Park J, Jang K. Radiographic and computed tomographic evaluation of experimentally induced lung aspiration sites in dogs. *J Vet Sci* 2006; **7**: 397–399.
- 29 Bajwa Sjs, Kulshrestha A. Diagnosis, prevention and management of postoperative pulmonary edema. *Ann Med Health Sci Res* 2012; **2**: 180.
- 30 Louis PJ, Fernandes R. Negative pressure pulmonary edema. *Oral Surg Oral Med Oral Pathol Oral Radiol Endod* 2002; **93**: 4–6.
- 31 Dunié-Mérigot A, Bouvy B, Poncet C. Comparative use of CO<sub>2</sub> laser, diode laser and monopolar electrocautery for resection of the soft palate in dogs with brachycephalic airway obstructive syndrome. *Vet Rec* 2010; **167**: 700–704.
- 32 Shin CW, Son W gyun, Jang M, Kim H, Han H, Cha J *et al*. Selection of appropriate endotracheal tube size using thoracic radiography in Beagle dogs. *Vet Anaesth Analg* 2018; **45**: 13–21.
- 33 Emmerson T. Brachycephalic obstructive airway syndrome: a growing problem. *J Small Anim Pract* 2014; **55**: 543–544.
- 34 Ellis J, Ann Leece E. Nebulized Adrenaline in the Postoperative Management of Brachycephalic Obstructive Airway Syndrome in a Pug. *J Am Anim Hosp Assoc* 2017; **53**: 107–110.

Page 13 of 16

54  
55  
56  
57  
58  
59  
60

Veterinary Record Case Reports

- 35 Nguyen D, Abdul-Rasool I, Ward D, Hsieh J, Kobayashi D, Hadlock S *et al.* Ventilatory effects of dexmedetomidine, atipamezole, and isoflurane in dogs. *Anesthesiology* 1992; **76**: 573–9.
- 36 Ko JC, Bailey JE, Pablo LS, Heaton-Jones TG. Comparison of sedative and cardiorespiratory effects of medetomidine and medetomidine-butorphanol combination in dogs. *Am J Vet Res* 1996; **57**: 535–40.
- 37 Pascoe PJ, Moon PF. Periparturient and neonatal anesthesia. *Vet Clin North Am - Small Anim Pract* 2001; **31**: 315–341.
- 38 Grubb, T. L., Perez Jimenez, T. E. and Pettifer GR. Neonatal and Pediatric Patients. In: K. A. Grimm, L. A. Lamont, W. J. Tranquilli SAG and SAR (ed). *Veterinary Anesthesia and Analgesia*. Wiley Blackwell, 2017, pp 983–987.
- 39 Bhaskar B, Fraser JF. Negative pressure pulmonary edema revisited: Pathophysiology and review of management. *Saudi J Anaesth* 2011; **5**: 308–13.
- 40 Wong A, Uquillas E, Hall E, Dart C, Dart A. Comparison of the effect of oxygen supplementation using flow-by or a face mask on the partial pressure of arterial oxygen in

- sedated dogs. *N Z Vet J* 2019; **67**: 36–39.
- 41 Strollo P, Rogers R. Current Concepts: Obstructive Sleep Apnea. *N Engl J Med* 1996; **334**: 1–6.
- 42 Agarwal R, Aggarwal AN, Gupta D. Non-invasive ventilation in acute cardiogenic pulmonary oedema. *Postgr Med J* 2005; **81**: 637–643.
- 43 McNeill GBS, Glossop AJ. Clinical applications of non-invasive ventilation in critical care. *Contin Educ Anaesthesia, Crit Care Pain* 2012; **12**: 33–37.
- 44 Bellone A, Vettorello M, Monari A, Cortellaro F, Coen D, Bellone A *et al*. Noninvasive pressure support ventilation vs. continuous positive airway pressure in acute hypercapnic pulmonary edema. *Intensive Care Med* 2005; **31**: 807–811.
- 45 Briganti A, Melanie P, Portela D, Breggi G, Mama K. Continuous positive airway pressure administered via face mask in tranquilized dogs. *J Vet Emerg Crit Care* 2010; **20**: 503–508.
- 46 Staffieri F, Crovace A, De Monte V, Centonze P, Gigante G, Grasso S. Noninvasive continuous positive airway pressure delivered using a pediatric helmet in dogs recovering from general anesthesia. *J Vet Emerg Crit Care (San Antonio)* 2014; **24**: 578–85.
- 47 Meira C, Joerger FB, Kutter APN, Waldmann A, Ringer SK, Böehm SH *et al*. Comparison of three continuous positive airway pressure (CPAP) interfaces in healthy Beagle dogs during medetomidine–propofol constant rate infusions. *Vet Anaesth Analg* 2018; **45**: 145–157.
- 48 Bruniges N, Rigotti C. Postanaesthetic pulmonary oedema in a dog following intravenous naloxone administration after upper airway surgery. *Vet Rec Case Reports* 2017; **5**: 1–6.
- 49 Wiesen J, Ornstein M, Tonelli AR, Menon V, Ashton RW. State of the evidence: mechanical ventilation with PEEP in patients with cardiogenic shock. *Heart* 2013; **99**: 1812–7.



Veterinary Record Case Reports

- 50 Paré PD, Warriner B, Baile EM, Hogg JC. Redistribution of Pulmonary Extravascular Water with Positive End-expiratory Pressure in Canine Pulmonary Edema. *Am Rev Respir Dis* 1983; **127**: 590–593.
- 51 Malo J, Ali J, Wood LD. How does positive end-expiratory pressure reduce intrapulmonary shunt in canine pulmonary edema? *J Appl Physiol* 1984; **57**: 1002–1010.
- 52 Keir I, Daly J, Haggerty J, Guenther C. Retrospective evaluation of the effect of high flow oxygen therapy delivered by nasal cannula on PaO<sub>2</sub> in dogs with moderate-to-severe hypoxemia. *J Vet Emerg Crit Care* 2016; **26**: 598–602.
- 53 Purvey M, Allen G. Managing acute pulmonary oedema. *Aust Prescr* 2017; **40**: 59–63.
- 54 McConkey PP. Postobstructive pulmonary oedema - A case series and review. *Anaesth Intensive Care* 2000; **28**: 72–76.
- 55 Sumner C, Rozanski E. Management of respiratory emergencies in small animals. *Vet Clin*

1  
2  
57  
58  
59  
60

	<i>North Am - Small Anim Pract</i> 2013; <b>43</b> : 799–815.
56	Licker M, Tschopp JM, Robert J, Frey JG, Diaper J, Ellenberger C. Aerosolized salbutamol accelerates the resolution of pulmonary edema after lung resection. <i>Chest</i> 2008; <b>133</b> : 845–852.
57	Krodel DJ, Bittner EA, Abdunour R, Brown R, Eikermann M. Case Scenario: Acute Postoperative Negative Pressure Pulmonary Edema. <i>Anesthesiology</i> 2010; <b>113</b> : 200–207.
58	Lang SA, Duncan PG, Shephard DAE, Ha HC. Pulmonary oedema associated with airway obstruction. <i>Can J Anaesth</i> 1990; <b>37</b> : 210–218.
59	Papadimos T, Vandse R, Kothari D, Tripathi R, Lopez L, Stawicki SA. Negative pressure pulmonary edema with laryngeal mask airway use: Recognition, pathophysiology and treatment modalities. <i>Int J Crit Illn Inj Sci</i> 2012; <b>2</b> : 98.
<b>FIGURE/VIDEO CAPTIONS</b> <i>figures should NOT be embedded in this document</i>	
<b>OWNER'S PERSPECTIVE</b> <i>Optional</i>	
<b>Copyright Statement</b>	

54  
55  
56  
57  
58  
59  
60

Veterinary Record Case Reports

I, *Luis Filipe Louro*, The Corresponding Author, has the right to assign on behalf of all authors and does assign on behalf of all authors, a full assignment of all intellectual property rights for all content within the submitted case report (other than as agreed with the BMJ Publishing Group Ltd and the British Veterinary Association) ("BMJ" and "BVA") in any media known now or created in the future, and permits this case report (if accepted) to be published on Veterinary Record Case Reports and to be fully exploited within the remit of the assignment as set out in the assignment which has been read <http://journals.bmj.com/site/misc/vetreccrcopyright.pdf>

**Date: 04/07/2019**

---


**PLEASE SAVE YOUR TEMPLATE WITH THE FOLLOWING FORMAT:**

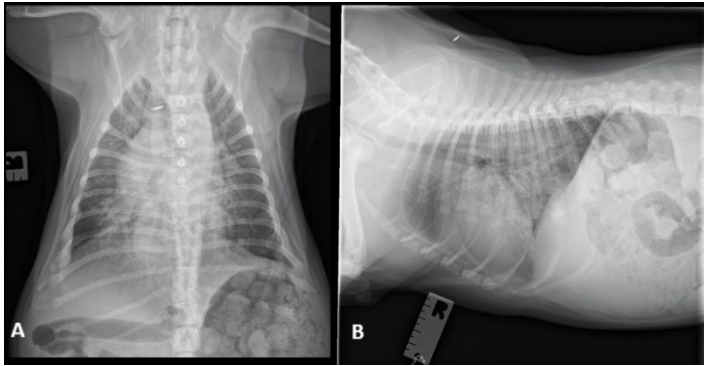
Corresponding author's last name and date of submission, eg,

Smith\_June\_2017.doc

1  
2

54  
55  
56  
57  
58  
59  
60





4 Fig.1. (A) Dorsoventral thoracic radiograph during inspiration. (B) Right lateral thoracic radiograph during  
5 inspiration. In these images it is possible to identify a generalised increase in soft tissue and ground glass  
6 opacities of the pulmonary parenchyma, associated with multiple air bronchograms. The pulmonary lesions are  
7 more severe in the perihilar region and reduced in severity towards the periphery. The border of the cardiac  
8 silhouette was partially effaced by the neighbouring lung changes, but the cardiac silhouette was not enlarged.

165x85mm (300 x 300 DPI)

# Veterinary Record casereports

## Submission template for full cases

All case reports MUST be submitted online using this Word template. Please refer to the [template](#) so you know what to include in each section [Hints and Tips](#)

o <http://mc.manuscriptcentral.com/vetreccr>

o You will be asked for more detailed information on submission where you can also upload images, multimedia files, etc 15 o Further details are available in the [Instructions for authors](#) 16 17 For studies using client-owned animals the article must demonstrate a high standard (best practice) of 18 veterinary care and have informed client consent 19

20 You, your practice or institution must be a subscriber to Veterinary Record Case Reports in order to 21 submit. Subscribers can submit as many cases as they like, access all the published material, and re-use 22 any published material for personal use and teaching without further permission.

23 o For more information on rates and how to purchase your subscription visit

24 <http://vetrecordcasereports.bmj.com/site/about/Subslanding.xhtml>

25 o Contact your librarian, head of department or practice owner to see if your institution already has a subscription

<b>TITLE OF CASE <i>Do not include "a case report"</i></b>
POSTOBSTRUCTIVE NEGATIVE PRESSURE PULMONARY OEDEMA IN A DOG
<b>SUMMARY <i>Up to 150 words summarising the case presentation and outcome (this will be freely available online)</i></b>

28  
29  
30  
31  
32  
33  
34  
35  
36  
37  
38  
39  
40  
41  
42  
43  
44  
45  
46  
47  
48  
49  
50  
51  
52  
53

A four-month-old English bulldog was anaesthetised for investigation and management of chronic urinary incontinence. In the post-anaesthetic period the patient developed respiratory distress, with marked cough and increased inspiratory effort. Diagnostic imaging suggested pulmonary oedema. After excluding all other causes of cardiogenic and non-cardiogenic pulmonary oedema it was hypothesised that the patient developed post-anaesthetic negative pressure pulmonary oedema, suspected to have been exacerbated by tracheal intubation with an oversized endotracheal tube leading to laryngeal swelling and obstruction. The animal was treated with oxygen supplementation, corticosteroids and  $\beta$ -2 adrenergic receptor agonists. The patient recovered from the event and was discharged from the hospital after forty-eight hours. This article discusses in further details other management options of negative pressure pulmonary oedema. This is the first case report discussing the pathophysiology, critical care and management of post-anaesthetic negative pressure pulmonary oedema in a dog.

**BACKGROUND** *Why you think this case is important – why did you write it up?*

1  
2

Pulmonary oedema is defined as an abnormal accumulation of fluid in the extravascular tissues and spaces of the lung that occurs when the lymphatic circulation is unable to drain the excessive fluid present in the extravascular space <sup>1</sup>.

Post-obstructive pulmonary oedema can be subdivided into two types: Type 1 which is associated with an increase in inspiratory effort due to an acute upper airway obstruction (UAO) and type 2 which results from a relief of a chronic partial UAO (e.g. after laryngeal mass resection) <sup>2</sup>. Postobstructive pulmonary oedema type 1 is also known as negative pressure pulmonary oedema (NPPO) and has been highlighted as a potential complication in the post-anaesthetic period in people and horses<sup>3,4</sup>. Multiple causes have been attributed to the development of NPPO:

brachycephalic obstructive airway syndrome (BOAS), strangulation, choking, near drowning, airway collapse, laryngeal mass, laryngeal paralysis, endotracheal tube (ETT) obstruction, laryngospasm and partial occlusion of the upper airway tract with a foreign body or other mass <sup>2,5</sup>.

now accepted that this multifactorial process involving negative pressures and hypoxia<sup>2</sup>.

The pathophysiologic mechanism behind NPPO was primarily described in the 1940s <sup>6</sup> and it is is a

Physiologically the UAO creates a large negative transpulmonary and interpleural pressure gradient favouring movement of fluid from the capillaries through the alveolar capillary barrier into the extravascular space <sup>3</sup>. This increase in hydrostatic pressures and oedema formation in the lungs <sup>2,7</sup>, contributes to the overall translocation of fluid from the capillaries into the alveolar spaces.

In the veterinary literature few reports have been published discussing this event. In 1927, a research article reporting the response to respiratory resistance in dogs found that a partial fixed obstruction during a prolonged inspiratory phase resulted in lesions compatible with pulmonary oedema at post-mortem examination <sup>8</sup>. In 1989 and 1995, two case series described the development of pulmonary oedema in conscious dogs due to UAO resulting from laryngeal paralysis, laryngeal oedema or obstructive airway masses <sup>9,10</sup>. Another case series was recently published describing the radiographic appearance of 23 cases with presumed post-obstructive pulmonary oedema in conscious dogs <sup>5</sup>.

To the authors knowledge this is the first case report in the veterinary literature describing the

54  
55  
56  
57  
58  
59  
60



1 pathophysiology, critical care and management of post-anaesthetic NPPO in a dog.  
2  
3  
4  
5  
6  
7  
8  
9  
10  
11  
12  
13  
14  
15  
16  
17  
18  
19  
20  
21  
22  
23  
24  
25  
26  
27  
28  
29  
30  
31  
32  
33  
34  
35  
36  
37  
38  
39  
40  
41  
42  
43  
44  
45  
46  
47  
48

49 **CASE PRESENTATION** *Presenting features, clinical and environmental history*  
50


51  
52  
53 A four-month-old, 11.6 kg, body condition score 6/9 <sup>11</sup>, female English Bulldog was presented for  
54 investigation and management of chronic urinary incontinence of one-month duration. At  
55 presentation the patient was bright and alert. Clinical examination revealed a recessed vulva and  
56

1  
2  
57  
58  
59  
60

Page 2 urine-stained fur in the peri-vulvar area. Thoracic auscultation was unremarkable, respiratory rate

of 16

54  
55  
56  
57  
58  
59  
60



was 32 rpm and no obvious BOAS was detected. Cardiac auscultation was unremarkable (no murmurs detected) and the heart rate was 140 bpm with regular rhythm. Temperature recorded was 38°C. Blood haematology and serum biochemistry were unremarkable. An American Society of Anaesthesiology (ASA) physical status classification of 2 was assigned to the dog<sup>12</sup>. A Computed Tomography (CT) scan of the thorax and abdomen, under sedation, was scheduled for the same day. The patient was premedicated with 0.01mg/kg medetomidine (Medetor, Virbac) and 0.2mg/kg butorphanol (Dolorex, MSD Animal Health) by intramuscular injection. A 22 gauge intravenous cannula was placed aseptically in the left cephalic vein. Oxygen was supplemented via face mask throughout the sedation period at a flow rate of 4L/min. Fluid therapy was initiated, before CT contrast was administered, with Hartmann's Solution (Aquapharm 11, Animacare) at a rate of 4mL/kg/hr. Pulse oximetry, non-invasive oscillometric blood pressure measurement, pulse rate and respiratory rate were monitored using a multiparameter monitor (Datex-Ohmeda S/5, GE Healthcare).

CT examination of the abdomen following intravenous injection of contrast medium revealed dilation of the urethra with absence of normal vesiculourethral junction and mild dilation of the left ureter.

A retrograde vaginourethrogram was immediately performed under general anaesthesia, after the CT scan. Propofol 2mg/kg (PropoFlo Plus, Zoetis) was administered intravenously. The trachea was intubated using a cuffed (high volume, low pressure) 8 mm inner diameter polyvinyl chloride (PVC) ETT. No difficulties were encountered during tracheal intubation although the ETT was found to be close-fitting as no cuff inflation was required when leak testing the system. General anaesthesia was maintained with sevoflurane (SevoFlo, Zoetis) vaporised in 100 per cent oxygen. Anaesthetic monitoring included electrocardiography, pulse oximetry, capnography and noninvasive oscillometric blood pressure measurement using a multiparameter monitor (DatexOhmeda S/5, GE Healthcare). The trachea was extubated as soon as the patient swallowed, no complications were detected at that time, and no fluid or foam were visualised in the ETT. There were no breathing difficulties or signs of gastroesophageal reflux (GOR) detected after extubation. The patient was hypothermic in the recovery period (35.9°C). In order to treat the hypothermia active warming was initiated with an active warming device (Hot Dog Patient Warming; Augustine Surgical Inc) and further temperature measurements were performed until the hypothermia resolved three hours after extubation. The patient was kept on intravenous fluid therapy for fifteen hours at a rate of 4ml/kg/hr, using a fluid pump, in order to avoid CT contrast induced nephropathy<sup>13</sup>. Fluid therapy guidelines suggest maintenance fluid rates between 2-6 ml/kg/hr in healthy dogs<sup>14</sup>. Well-hydrated patients are generally able to regulate and excrete this fluid volumes. Although unlikely, this fluid therapy

patients with normal renal and heart function

1  
2

Page 3  
of 16

regime may have predisposed the patient to volume overload. 8

The animal was hospitalised overnight and was examined evening am, fourteen hours after considered clinically normal for the last time at 4am. At general

marked increase in inspiratory effort and anaesthesia, clinical examination of the patient revealed coughing, respiratory distress with a

auscultation increased upper respiratory sounds and wheeze respiratory rate of 40 rpm. During thoracic noticed. On cardiac auscultation, no heart murmur was heard, the heart rate was 124 bpm, mucous membranes were pink and was one second. Rectal temperature measured was 38,7°C. performed to establish the origin of the sudden onset of res regurgitation followed by aspiration and subsequent pneumon

**INVESTIGATIONS *If relevant***

54  
55  
56  
57  
58  
59  
60


1  
2  
3  
4 In order to perform radiographs, the patient was sedated with 0.001mg/kg medetomidine (Medetor,  
5 Virbac) and 0.2mg/kg butorphanol (Dolorex, MSD Animal Health) intravenously. Dorsoventral  
6 and lateral inspiratory thoracic radiographs were obtained (Fig.1). A generalised increase in soft  
7 tissue and ground glass opacities of the pulmonary parenchyma was identified, associated with  
8 multiple air bronchograms (unstructured interstitial and alveolar lung patterns). The pulmonary  
9 lesions were more severe in the perihilar region and reduced in severity towards the periphery. The  
10 border of the cardiac silhouette was partially effaced by the neighbouring lung changes, but the  
11 cardiac silhouette was not enlarged. Retrospectively, the CT of the caudal thorax earlier performed  
12 revealed no abnormalities in the caudal two thirds of the lungs. Tracheal inner diameter measured  
13 8.92mm and thoracic inlet measurement 6.67cm. The trachea : thoracic inlet ratio was within  
14 normal limits for a English Bulldog (0.134) <sup>15,16</sup>.

20  
21 Due to the more severe pulmonary lesions in the perihilar region suggesting the possibility of  
22 cardiogenic pulmonary oedema, a single dose of furosemide at 2mg/kg was administered  
23 intravenously promptly and an echocardiography was performed. Neither left nor right atrial  
24 enlargement was identified and systolic function appeared normal. There were no valvular  
25 regurgitations and no evidence of increased filling pressures detected; therefore, cardiogenic  
26 cause of pulmonary oedema was discarded.

30  
31 The pharynx and the larynx were visually examined using laryngoscope with a light source with  
32 the animal profoundly sedated. The larynx was found to be grossly inflamed with erythema and  
33 swelling of the area. No mass, foreign body, laryngeal paralysis or other source of UAO was  
34

1  
2  
57  
58  
59  
60

54  
55  
56  
57  
58  
59  
60



1 identified during examination.  
2  
3

4 **DIFFERENTIAL DIAGNOSIS *If relevant***

5  
6  
7  
8 From the history, presentation and radiographic findings a non-cardiogenic pulmonary oedema  
9 was highly suspected. Alternative differential diagnoses included idiopathic interstitial  
10 pneumonia, neoplastic infiltration or non-witnessed aspiration pneumonia.  
11  
12

13  
14 A presumptive diagnosis of post-anaesthetic NPPO was made.  
15  
16  
17  
18  
19  
20  
21

22  
23  
24  
25  
26  
27  
28  
29  
30  
31  
32  
33  
34  
35  
36  
37  
38  
39  
40  
41  
42  
43  
44  
45  
46  
47  
48  
49  
50  
51  
52  
53  
54  
55  
56  
57

1  
2  
3  
4  
5  
6  
7  
8  
58  
59  
60

**TREATMENT *If relevant***

The dog was transferred to the intensive care unit. The patient showed laboured breathing and a significant stertor could be heard. Positioning the patient with the neck extended significantly improved the level of comfort. A continuous rate infusion of butorphanol (Dolorex; MSD

Animal Health) at 0.2mg/kg/hr was started to provide sedation, analgesia and antitussive therapy with minimal respiratory depression<sup>17,18</sup>. Oxygen supplementation via nasal prongs was implemented at a flow rate of 1.5L min<sup>-1</sup>. Saturation of haemoglobin with oxygen was monitored using a portable pulse oximeter (Radical 7 Pulse Oximeter; Masimo). No episodes of patient's desaturation were reported, pulse oximeter values were always above 95% of saturation of haemoglobin with oxygen.

Salbutamol nebulization therapy (Ventolin; Glaxo Smith Klein) was initiated at a dose of 0.035 mg/kg TID administered via metered dose inhalers over periods of 6 breaths using an aerosol chamber with a fitted face mask (AeroDawg; Truddel Medical International).

Therapy with dexamethasone (0.2mg/kg IV SID) (Colvasone, Norbook); omeprazole (1mg/kg IV BID) (Omeprazole; Star Pharmaceuticals Ltd.); and cefuroxime (20mg/kg IV TID) (Zinacef; GlaxoSmithKlein) was initiated due to the possibility of regurgitation followed by aspiration and subsequent pneumonia.

54  
55  
56  
57  
58  
59  
60



**OUTCOME AND FOLLOW-UP**

The animal responded well to treatment. Sixteen hours after the initial clinical signs, the patient was bright and alert. Respiratory rate decreased (20 rpm), no cough or increased inspiratory effort was detected. All medications were discontinued 36 hours after recognition of the clinical signs.

The animal was discharged from the hospital 48 hours after this event. Unfortunately, no follow up imaging was performed.

Six months after discharge the animal has fully recovered from this episode with no complications arising from the NPPO.

**DISCUSSION** *Include a very brief review of similar published cases***DIFFERENTIAL DIAGNOSIS**

The possibility of aspiration and secondary pneumonia was initially suspected before diagnostic imaging was performed. In anaesthetised dogs, gastric oesophageal reflux (GOR) has a high

1  
2  
3  
4  
5  
6  
7  
8  
57  
58  
59  
60

incidence, which ranges from 16 per cent<sup>19</sup> to 55 per cent<sup>20</sup>. A clinical trial showed a higher incidence of GOR (60 per cent vs 40 per cent) when comparing anaesthetised brachycephalic and non-brachycephalic dogs, although this was not statistically significant<sup>21</sup>. This is, in part, related to the high negative intrathoracic pressures generated to overcome the upper respiratory tract obstruction<sup>22-24</sup>. GOR is associated with an increased risk of aspiration and secondary pneumonia<sup>22,24</sup>.

9  
10  
11  
12  
13  
14  
15  
16  
18  
19  
20  
21  
22  
23  
24  
25  
26  
27  
28  
54  
55  
56  
57  
58  
59  
60

In this case we excluded the possibility of aspiration pneumonia as the cause of the pulmonary oedema due to the rapid resolution of the clinical signs. Two studies reflected on the duration of hospitalization for dogs with aspiration pneumonia and resolution of clinical signs. Results showed in these studies ranged from 3 to 5 days of hospitalization in the intensive care unit for 17 dogs recovering from aspiration pneumonia<sup>25,26</sup>.

In terms of radiography, there are different radiographic appearances when comparing NPPO to aspiration pneumonia. In aspiration pneumonia the most gravity dependent areas are the most affected<sup>27</sup>. The positioning of the patient during aspiration may predict the location of pulmonary infiltrates. In sternal recumbency it is more likely that the right lung is affected, as the right mainstem bronchus is a more direct prolongation of the trachea than the left. In ventrodorsal

29 positioning the caudal lung lobes seem to be more affected <sup>28</sup>. A recent case series focused on the  
30  
31 radiographic appearance of non-cardiogenic pulmonary oedema suggested that a dorsal  
32  
33 distribution of the lung lesions seemed to be more often observed in NPPO than in other causes of  
34  
35 non-cardiogenic pulmonary oedema, although, the authors could not give an explanation to this  
36 finding<sup>5</sup>.

37  
38  
39 In dogs with experimentally induced lung aspiration, radiographic signs were only seen 24 hours  
40  
41 post aspiration and clinical signs of cough and respiratory distress were only present two days  
42 <sup>28</sup>. In this case, clinical signs and radiographic changes occurred between ten to 43 after the  
event

44 fourteen hours after extubation, although aspiration before sedation cannot be excluded. Also,  
45  
46 abnormal radiographic findings were mainly caudodorsally located which differs from cases of  
47  
48 aspiration pneumonia. In human medicine, this post-anaesthetic complication has a variable  
49 onset of clinical signs, it may vary from few minutes to several hours (up to 24 hours) following  
50  
51 extubation or relief of obstruction <sup>2,29,30</sup>. Delayed onset of laryngeal oedema due to trauma has  
52  
53 been reported as a complication of the surgical treatment of BOAS in dogs<sup>31</sup>. In one case series,  
four dogs developed laryngeal oedema post-surgery. The onset of clinical signs of upper airway  
obstruction, such as increased respiratory effort and cyanosis, were noted one, three, seven and ten  
hours after surgery. The authors mentioned that the laryngeal oedema could have resulted from  
surgery trauma or induced by the ETT<sup>31</sup>.

1 Other causes of non-cardiogenic pulmonary oedema, such as direct lung injury (fire smoke  
2 exposure, toxin inhalation); neurogenic oedema (electrocution); systemic disease (neoplasia,  
3 uremic syndrome, pancreatitis); near drowning; blood transfusion; anaphylaxis<sup>5</sup> were also  
4 discarded by clinical history, clinical examination and blood analysis. Neurogenic oedema due to  
5 seizures is difficult to completely exclude as the animal was not constantly monitored overnight  
6 and a seizure episode cannot be completely excluded. Although, to date, no history or clinical signs  
7 of neurologic disease have been reported in this patient, therefore the main causes of neurogenic  
8 pulmonary oedema were considered unlikely.

#### 12 CONTRIBUTION FACTORS FOR THE DEVELOPMENT OF NPPO

##### 13 PATHOPHYSIOLOGY

14 It is believed that the animal described here suffered from type 1 post-  
15 obstructive pulmonary  
16 oedema, due to a suspected upper airway obstruction caused by gross swelling and erythema of the  
17 larynx. This may have been exacerbated from suspected trauma during tracheal intubation with an  
18 oversized ETT. A recent study in Beagles suggested that a suitably sized ETT for dogs should  
19 measure 70% of the internal tracheal diameter measured on thoracic radiography<sup>32</sup>. In this  
20 particular case, the measurement using the same method revealed 8.92mm internal tracheal  
21 diameter which corresponds to a 6.2mm ETT. An 8mm ETT was used to intubate the trachea of  
22 this patient, which could potentially explain the laryngeal swelling, erythema and secondary post  
23 extubation UAO.  
24

##### 25 BOAS


26 BOAS has an impact on the management of these patients during anaesthesia and recovery<sup>22</sup>.  
27 BOAS is characterised by dynamic and/or static UAO<sup>33</sup>. These patients are subjected to an  
28 increased resistance to inspiratory airflow which results in increased inspiratory effort and the  
29 generation of supraphysiologic negative thoracic and airway pressures<sup>33</sup>. In severe cases of BOAS,  
30 UAO can result in NPPO<sup>22</sup>. In our patient brachycephalic conformation may have played a role in  
31 aggravating the UAO.  
32

##### 33 SEDATION

34 This animal was sedated with a low dosage of medetomidine to safely perform the radiographs and  
35 the echocardiography. In cases of NPPO,  $\alpha_2$ -agonists must be used with caution. Profound sedation  
36 with this class of drugs induces recumbency, reduces pharyngeal muscle tone and may predispose  
37 to hypoventilation. All of these factors can theoretically worsen any UAO already present<sup>22,34</sup>. On  
38 the other hand, sedation may be useful in controlling excessive panting associated with stress,  
39 reducing further airway swelling or collapse and decreasing oxygen consumption<sup>22</sup>. This patient  
40 was closely monitored for signs of UAO including increased stertor/stridor, increased inspiratory  
41 effort and exaggerated movement of the chest wall.  
42

1  
2  
3  
4  
5  
6  
7  
8  
57  
58  
59  
60

54  
55  
56  
57  
58  
59  
60



9 Elevating the patient's head improved the audible stertor/stridor during sedation. Oxygen was  
10 supplemented via face mask and haemoglobin saturation with oxygen was monitored via pulse  
11 oximetry at all times during this process. If necessary antipamezole could have been administered  
12 in this case, as this  $\alpha_2$ -antagonist counteracts the respiratory depression caused by the  
13 administration of  $\alpha_2$ -agonists<sup>35,36</sup>. Butorphanol can be used to provide sedation, analgesia and  
14 antitussive therapy with minimal respiratory depression in cases of respiratory distress and was  
15 used successfully<sup>17,18</sup>.

#### 16 PAEDIATRIC PATIENT

17 The fact that this was a paediatric patient may have played a role in the development of pulmonary  
18 oedema in this case. Young animals have a smaller functional residual capacity, therefore they will  
19 quickly develop hypoxia in the event of an UAO<sup>37,38</sup>. The rib cage of young animals is very  
20 compliant, resulting in less competent ventilation and greater work of breathing. This may  
21 predispose paediatric patients to hypoxia and ventilatory fatigue, which can be aggravated in the  
22 event of an UAO<sup>38</sup>. The larynx of puppies is delicate, and extreme care should be taken to intubate  
23 the trachea atraumatically<sup>37</sup>. This patient was 4 months old and intubation of the trachea was  
24 performed with an oversized ETT which potentially caused the laryngeal oedema, which was  
25 theorised to be the cause of the UAO. Hypoxia may have developed quicker in this patient for the  
26 reasons described above.  
27  
28  
29  
30

#### 31 TREATMENT

32 The priorities in patients presenting NPPO are to relieve the UAO and correct the hypoxaemia.  
33 Supportive care should be implemented aiming to maintain a patent airway and ensuring adequate  
34 oxygenation<sup>2,39</sup>. Oxygen supplementation, continuous positive airway pressure (CPAP),  
35 intermittent positive pressure ventilation (IPPV) and positive end-expiratory pressure (PEEP) are  
36 methods used to fulfil those goals. Other medications such as glucocorticoids and  $\beta_2$ -agonists are  
37 also used to minimize the UAO.  
38  
39  
40  
41

#### 42 OXYGEN SUPPLEMENTATION

43 Traditional oxygen therapy is most usually provided via a face mask, nasal prongs or oxygen  
44 cage, delivering dry, cold oxygen with FIO<sub>2</sub> of 40 to 70% at flow rates of 50 –150 mL/kg/min<sup>40</sup>.

47 In a research project including twenty healthy dogs, the mean partial pressure of oxygen (PaO<sub>2</sub>) in  
48 arterial samples taken after face mask oxygen supplementation was 371.3 mmHg compared to the  
49 control group composed by dogs breathing room air (82.43 mmHg)<sup>40</sup>. Passive oxygen  
50 administration via a nasal prongs was chosen in this case to provide oxygen to the patient.  
51 Unfortunately, no arterial blood gas analysis was performed; this could have provided more reliable  
52 information regarding the haemoglobin saturation with oxygen and PaO<sub>2</sub>.  
53

#### CPAP

CPAP is a mode of ventilation used in spontaneously breathing subjects. This is used in humans

1 for the treatment of NPPO and sleep apnoea<sup>41</sup>. The objective of CPAP is to maintain a positive  
2 pressure in the airways during inspiration and expiration. This intrathoracic positive pressure at the  
3 end of expiration will improve alveolar ventilation and re-expand flooded alveoli, promoting the  
4 fluid to return to the interstitial space<sup>42</sup>. Other benefits of CPAP include a reduction in preload due  
5 to an increase in intrathoracic pressure and a reduction in afterload, via an increase in pericardial  
6 pressure and reduction in transmural pressure<sup>42</sup>. It also improves oxygenation, gas exchange, vital  
7 signs and reduces work of breathing<sup>43,44</sup>. One of the advantages of CPAP delivery is that there is  
8 no need for tracheal intubation and mechanical ventilation. No CPAP delivering devices have been  
9 designed for veterinary patients. Two human interfaces for CPAP delivery have been studied in  
10 dogs,<sup>45,46</sup>. In healthy sedated dogs, when comparing CPAP via face mask with traditional oxygen  
11 therapy delivered via regular face mask, CPAP increased PaO<sub>2</sub> by 102 mmHg and was well  
12 tolerated by the patients<sup>45</sup>. Disadvantages have been highlighted in a research project testing three  
13 methods of non-invasive CPAP delivery (custom-made mask, conical face mask and helmet):  
14 significant leaks were found when CPAP was delivered to sedated dogs. There is a significant risk  
15 of rebreathing and hypoxaemia when CPAP was not maintained. The authors concluded that  
16 animals should always be supervised during administration of CPAP<sup>47</sup>. In our patient this method  
17 of ventilation was not used because it was not available at the time, in our opinion it would have  
18 been a valid option for treatment of this patient because it would maintain a patent airway, improved  
19 oxygenation and reduced the work of breathing. Nevertheless, the temperament of the animal could  
20 have limited the use of CPAP in this case.

### 31 IPPV


32 IPPV with PEEP has been used in veterinary medicine for treatment of non-cardiogenic pulmonary  
33 oedema<sup>48</sup>. The application of PEEP counterbalances the hydrostatic forces leading to pulmonary  
34 oedema, redistributing the extravascular fluid from the alveoli into perivascular interstitium and  
35 maintaining airway patency<sup>49</sup>. PEEP also improves gas exchange and recruits alveolar units.  
36 Application of PEEP up to 13 cmH<sub>2</sub>O improved alveolar gas exchange in experimentally induced  
37 canine pulmonary oedema<sup>50,51</sup>. In this case IPPV and PEEP were not used because this would  
38 require endotracheal intubation which could have perpetuated the laryngeal inflammation already  
39 present. In human patients with NPPO, IPPV and PEEP are only implemented in severe cases of  
40 hypoxaemia, ventilation/perfusion mismatch and poor lung compliance<sup>2</sup>. IPPV and PEEP may  
41 present disadvantages when compared to other methods of ventilation such as CPAP. These  
42 included: an increased risk of morbidity and mortality; the development of pneumonia, volutrauma  
43 and barotrauma; requirements for expensive and specialised equipment and staff; higher costs of  
44 patient management in an ICU setting<sup>45,52</sup>.

### 52 FUROSEMIDE

53 In patients suffering from fluid overload, diuretics may play a part in the resolution of pulmonary  
54  
55  
56

1  
2  
3  
4  
5  
6  
7  
8  
57  
58  
59  
60

54  
55  
56  
57  
58  
59  
60





oedema, but in other cases their role remains uncertain<sup>53,54</sup>. The reasoning behind using diuretics in these cases is to attempt to decrease the intravascular volume and alter Starling's equation in favour of intra capillary filtration and oedema resolution<sup>30</sup>. Furosemide was administered after radiographs confirmed pulmonary oedema. We had a concern that our patient may have been fluid overloaded, as she received fluid therapy at a rate of 4ml/kg/hr for a period of fifteen hours. The echocardiography discarded that possibility as well as cardiogenic pulmonary oedema.

Therefore the use of furosemide could have been avoided in this particular case.

### **CORTICOSTEROIDS**

Upper airway inflammation is associated with airway narrowing and obstruction. This increases airway resistance, may perpetuate inflammation and worsen coughing episodes. In the short term glucocorticoids may be useful in animals with BOAS with pharyngeal or laryngeal swelling<sup>55</sup>. Glucocorticoids were used in this case after examination of the larynx, to decrease the inflammation detected in that area.

### **SALBUTAMOL**

$\beta_2$ -agonists may be useful in lower airway disease in dogs<sup>55</sup>. In human medicine, aerosolized salbutamol was found to accelerate the resolution of pulmonary oedema, improve blood oxygenation, and stimulate cardiovascular function after lung lobe resection<sup>56</sup>.  $\beta_2$ -agonists could potentially increase the rate of alveolar fluid clearance through increased active cation transport, which may well accelerate the resolution of the clinical signs of pulmonary oedema<sup>57,58</sup>. The use of  $\beta_2$ -agonists is current practice in the treatment of NPPO in human medicine<sup>59</sup>. Interstitial oedema may induce narrowing of the bronchial lumen. This can be detected on thoracic auscultation as wheezing sounds<sup>57</sup>. In our case, clear wheezing was detected on thoracic auscultation; therefore, nebulisation with salbutamol was initiated.

### **LEARNING POINTS/TAKE HOME MESSAGES 3 to 5 bullet points – this is a required field**

- Endotracheal intubation should be performed atraumatically with an appropriately sized ETT (in length and diameter). When intubating the trachea of a patient correct position of the patient, use of laryngoscope (which provides adequate light and visualization of the larynx) and appropriate depth of anaesthesia are extremely important to avoid complications.
- Delayed onset of laryngeal oedema resulting in NPPO is possible; therefore animals should be closely monitored in the post-operative period.
- NPPO is a potential complication in the pre-anaesthetic period and can be treated with oxygen supplementation, corticosteroids and short-acting  $\beta_2$ -agonists.


□ Early recognition of the clinical signs and establishment of a prompt diagnosis is extremely important in the outcome of the case.

## REFERENCES *Vancouver style*

- 1 West JB. Pulmonary Edema. In: *Pulmonary physiology and pathophysiology : an integrated, case-based approach*. Wolters Kluwer Health/Lippincott Williams & Wilkins, 2007, pp 94–104.
- 2 Udeshi A, Cantie SM, Pierre E. Postobstructive pulmonary edema. *J Crit Care* 2010; **25**: 508.e1–508.e5.
- 3 Lorch G, Sahn A. Post-Extubation Pulmonary Edema Following Anesthesia Induced by Upper Airway Obstruction: Are Certain Patients at Increased Risk? *Chest* 1986; **90**: 802–805.
- 4 Senior M. Post-anaesthetic pulmonary oedema in horses: A review. *Vet Anaesth Analg* 2005; **32**: 193–200.
- 5 Bouyssou S, Specchi S, Desquilbet L, Pey P. Radiographic Appearance of Presumed Noncardiogenic Pulmonary Edema and Correlation With the Underlying Cause in Dogs and Cats. *Vet Radiol Ultrasound* 2017; **58**: 259–265.
- 6 Warren MF, Peterson DK, Drinker CK. The effects of heightened negative pressure in the chest, together with further experiments upon anoxia in increasing the flow of lung lymph. *Am J Physiol Content* 1942; **137**: 641–648.
- 7 Guffin TN, Har-El G, Sanders A, Lucente FE, Nash M, York N. Acute postobstructive pulmonary edema. *Otolaryngol - Head Neck Surg* 1995; **112**: 235–237.
- 8 Moore RL, Binger CA. The Response To Respiratory Resistance : a Comparison of the Effects Produced By Partial Obstruction in the Inspiratory and Expiratory Phases of Respiration. *J Exp Med* 1927; **45**: 1065–80.
- 9 Drobatz KJ, Saunders HM, Pugh CR, Hendricks JC. Noncardiogenic pulmonary edema in dogs and cats: 26 cases (1987-1993). *J Am Vet Med Assoc* 1995; **206**: 1732–6.
- 10 Kerr LY. Pulmonary edema secondary to upper airway obstruction in the dog: a review of nine cases. *J Am Anim Hosp Assoc* 1989; **25**: 207–212.
- 11 Laflamme DP. Development and validation of a body condition score system for dogs. *Canine Pract* 1997; **22**: 10–15.
- 12 American Society of Anesthesiologists. American Society of Anesthesiologists: ASA Physical Status Classification System. *Am. Soc. Anesthesiol.* 2014; : 1–2.

1  
2  
3  
4  
5  
6  
7  
8  
57  
58  
59  
60

54  
55  
56  
57  
58  
59  
60



- 13 Wong GTC, Irwin MG. Contrast-induced nephropathy. *Br J Anaesth* 2007; **99**: 474–83.
- 14 Davis H, Jensen T, Johnson A, Knowles P, Meyer R, Rucinsky R *et al*. AAHA/AAFP Fluid Therapy Guidelines for Dogs and Cats\*. *J Am Anim Hosp Assoc* 2013; **49**: 149–159.
- 15 Harvey CE, Fink EA. Tracheal diameter: analysis of radiographic measurements in brachycephalic and nonbrachycephalic dogs. *J Am Anim Hosp Assoc* 1982; **18**: 570–576.
- 16 Ingman J, Näslund V, Hansson K. Comparison between tracheal ratio methods used by three observers at three occasions in English Bulldogs. *Acta Vet Scand* 2014; **56**: 79.
- 17 Dyson DH. Update on butorphanol tartrate: use in small animals. *Can Vet J* 1990; **31**: 120–121.
- 18 Cavanagh RL, Gyls JA, Bierwagen ME. Antitussive properties of butorphanol. *Arch Int Pharmacodyn Ther* 1976; **220**: 258–68.
- 19 Galatos AD, Raptopoulos D. Gastro-oesophageal reflux during anaesthesia in the dog: the effect of age, positioning and type of surgical procedure. *Vet Rec* 1995; **137**: 513–6.
- 20 Wilson D V, Evans AT, Miller R. Effects of preanesthetic administration of morphine on gastroesophageal reflux and regurgitation during anesthesia in dogs. *Am J Vet Res* 2005; **66**: 386–90.
- 21 Shaver SL, Barbur LA, Jimenez DA, Brainard BM, Cornell KK, Radlinsky MG *et al*. Evaluation of Gastroesophageal Reflux in Anesthetized Dogs with Brachycephalic Syndrome. *J Am Anim Hosp Assoc*; **53**: 24–31.
- 22 Downing F, Gibson S. Anaesthesia of brachycephalic dogs. *J Small Anim Pract* 2018; **59**: 725–733.
- 23 Boesch RP, Shah P, Vaynblat M, Marcus M, Pagala M, Narwal S *et al*. Relationship between upper airway obstruction and gastroesophageal reflux in a dog model. *J Investig Surg* 2005; **18**: 241–245.
- 24 Shaver SL, Barbur LA, Jimenez DA, Brainard BM, Cornell KK, Radlinsky MG *et al*. Evaluation of Gastroesophageal Reflux in Anesthetized Dogs with Brachycephalic Syndrome. *J Am Anim Hosp Assoc* 2017; **53**: 24–31.
- 25 Kogan DA, Johnson LR, Sturges BK, Jandrey KE, Pollard RE. Etiology and clinical outcome in dogs with aspiration pneumonia: 88 cases (2004–2006). *J Am Vet Med Assoc* 2008; **233**: 1748–1755.
- 26 Tart KM, Babski DM, Lee JA. Potential risks, prognostic indicators, and diagnostic and treatment modalities affecting survival in dogs with presumptive aspiration pneumonia: 125 cases (2005-2008). *J Vet Emerg Crit Care* 2010; **20**: 319–329.

1  
2  
3  
4  
5  
6  
7  
8  
9  
10  
11  
12  
13  
14  
15  
16  
17  
18  
19  
20  
21  
22  
23  
24  
25  
26  
27  
28  
29  
30  
31  
32  
33  
34  
35  
36  
37  
38  
39  
40  
41  
42  
43  
44  
45  
46  
54  
55  
56  
57  
58  
59  
60

27 Sherman R, Karagiannis M. Aspiration Pneumonia in the Dog: A Review. *Top Companion*

47  
48  
49  
50  
51  
52  
53Page 13  
of 16

- Anim Med* 2017; **32**: 1–7.
- 28 Eom K, Seong Y, Park H, Choe N, Park J, Jang K. Radiographic and computed tomographic evaluation of experimentally induced lung aspiration sites in dogs. *J Vet Sci* 2006; **7**: 397–399.
- 29 Bajwa Sjs, Kulshrestha A. Diagnosis, prevention and management of postoperative pulmonary edema. *Ann Med Health Sci Res* 2012; **2**: 180.
- 30 Louis PJ, Fernandes R. Negative pressure pulmonary edema. *Oral Surg Oral Med Oral Pathol Oral Radiol Endod* 2002; **93**: 4–6.
- 31 Dunié-Mérigot A, Bouvy B, Poncet C. Comparative use of CO<sub>2</sub> laser, diode laser and monopolar electrocautery for resection of the soft palate in dogs with brachycephalic airway obstructive syndrome. *Vet Rec* 2010; **167**: 700–704.
- 32 Shin CW, Son W gyun, Jang M, Kim H, Han H, Cha J *et al*. Selection of appropriate endotracheal tube size using thoracic radiography in Beagle dogs. *Vet Anaesth Analg* 2018; **45**: 13–21.
- 33 Emmerson T. Brachycephalic obstructive airway syndrome: a growing problem. *J Small Anim Pract* 2014; **55**: 543–544.
- 34 Ellis J, Ann Leece E. Nebulized Adrenaline in the Postoperative Management of Brachycephalic Obstructive Airway Syndrome in a Pug. *J Am Anim Hosp Assoc* 2017; **53**: 107–110.
- 35 Nguyen D, Abdul-Rasool I, Ward D, Hsieh J, Kobayashi D, Hadlock S *et al*. Ventilatory effects of dexmedetomidine, atipamezole, and isoflurane in dogs. *Anesthesiology* 1992; **76**: 573–9.

1  
2  
3  
4  
5  
6  
7  
8  
9  
10  
11  
12  
13  
14  
15  
16  
17  
18  
19  
20  
21  
22  
23  
24  
25  
26  
27  
28  
29  
30  
31  
32  
33  
34  
35  
36  
37  
38  
39  
40  
41  
42  
43  
44  
45  
46  
47  
48  
49  
50  
51  
52  
53  
54  
55  
56  
57  
58  
59  
60

36 Ko JC, Bailey JE, Pablo LS, Heaton-Jones TG. Comparison of sedative and cardiorespiratory effects of medetomidine and medetomidine-butorphanol combination in dogs. *Am J Vet Res* 1996; **57**: 535–40.

37 Pascoe PJ, Moon PF. Periparturient and neonatal anesthesia. *Vet Clin North Am - Small Anim Pract* 2001; **31**: 315–341.

38 Grubb, T. L., Perez Jimenez, T. E. and Pettifer GR. Neonatal and Pediatric Patients. In: K. A. Grimm, L. A. Lamont, W. J. Tranquilli SAG and SAR (ed). *Veterinary Anesthesia and Analgesia*. Wiley Blackwell, 2017, pp 983–987.

39 Bhaskar B, Fraser JF. Negative pressure pulmonary edema revisited: Pathophysiology and review of management. *Saudi J Anaesth* 2011; **5**: 308–13.

40 Wong A, Uquillas E, Hall E, Dart C, Dart A. Comparison of the effect of oxygen supplementation using flow-by or a face mask on the partial pressure of arterial oxygen in

45  
46  
47  
48  
49  
50  
51  
52  
53  
54  
55  
56  
57  
58  
59  
60Page 14  
of 16

- sedated dogs. *N Z Vet J* 2019; **67**: 36–39.
- 41 Strollo P, Rogers R. Current Concepts: Obstructive Sleep Apnea. *N Engl J Med* 1996; **334**: 1–6.
- 42 Agarwal R, Aggarwal AN, Gupta D. Non-invasive ventilation in acute cardiogenic pulmonary oedema. *Postgr Med J* 2005; **81**: 637–643.
- 43 McNeill GBS, Glossop AJ. Clinical applications of non-invasive ventilation in critical care. *Contin Educ Anaesthesia, Crit Care Pain* 2012; **12**: 33–37.
- 44 Bellone A, Vettorello M, Monari A, Cortellaro F, Coen D, Bellone A *et al.* Noninvasive pressure support ventilation vs. continuous positive airway pressure in acute hypercapnic pulmonary edema. *Intensive Care Med* 2005; **31**: 807–811.
- 45 Briganti A, Melanie P, Portela D, Breggi G, Mama K. Continuous positive airway pressure administered via face mask in tranquilized dogs. *J Vet Emerg Crit Care* 2010; **20**: 503–508.
- 46 Staffieri F, Crovace A, De Monte V, Centonze P, Gigante G, Grasso S. Noninvasive continuous positive airway pressure delivered using a pediatric helmet in dogs recovering from general anesthesia. *J Vet Emerg Crit Care (San Antonio)* 2014; **24**: 578–85.
- 47 Meira C, Joerger FB, Kutter APN, Waldmann A, Ringer SK, Böehm SH *et al.* Comparison of three continuous positive airway pressure (CPAP) interfaces in healthy Beagle dogs during medetomidine–propofol constant rate infusions. *Vet Anaesth Analg* 2018; **45**: 145–157.
- 48 Bruniges N, Rigotti C. Postanaesthetic pulmonary oedema in a dog following intravenous naloxone administration after upper airway surgery. *Vet Rec Case Reports* 2017; **5**: 1–6.



1  
2  
3  
4  
5  
6  
7  
8  
9  
10  
11  
12  
13  
14  
15  
16  
17  
18  
19  
20  
21  
22  
23  
24  
25  
26  
27  
28  
29  
30  
31  
32  
33  
34  
35  
36  
37  
38  
39  
40  
41  
42  
43  
44  
45  
46  
47  
48  
49  
50  
51  
52  
53  
54  
55  
56  
57  
58  
59  
60

49 Wiesen J, Ornstein M, Tonelli AR, Menon V, Ashton RW. State of the evidence: mechanical ventilation with PEEP in patients with cardiogenic shock. *Heart* 2013; **99**: 1812–7.

50 Paré PD, Warriner B, Baile EM, Hogg JC. Redistribution of Pulmonary Extravascular Water with Positive End-expiratory Pressure in Canine Pulmonary Edema. *Am Rev Respir Dis* 1983; **127**: 590–593.

51 Malo J, Ali J, Wood LD. How does positive end-expiratory pressure reduce intrapulmonary shunt in canine pulmonary edema? *J Appl Physiol* 1984; **57**: 1002–1010.

52 Keir I, Daly J, Haggerty J, Guenther C. Retrospective evaluation of the effect of high flow oxygen therapy delivered by nasal cannula on PaO<sub>2</sub> in dogs with moderate-to-severe hypoxemia. *J Vet Emerg Crit Care* 2016; **26**: 598–602.

53 Purvey M, Allen G. Managing acute pulmonary oedema. *Aust Prescr* 2017; **40**: 59–63.

54 McConkey PP. Postobstructive pulmonary oedema - A case series and review. *Anaesth Intensive Care* 2000; **28**: 72–76.

55 Sumner C, Rozanski E. Management of respiratory emergencies in small animals. *Vet Clin*

47  
48  
49  
50  
51  
52  
53

Page 15  
of 16

*North Am - Small Anim Pract* 2013; **43**: 799–815.

56 Licker M, Tschopp JM, Robert J, Frey JG, Diaper J, Ellenberger C. Aerosolized salbutamol accelerates the resolution of pulmonary edema after lung resection. *Chest* 2008; **133**: 845–852.

57 Krodel DJ, Bittner EA, Abdulnour R, Brown R, Eikermann M. Case Scenario: Acute Postoperative Negative Pressure Pulmonary Edema. *Anesthesiology* 2010; **113**: 200–207.

58 Lang SA, Duncan PG, Shephard DAE, Ha HC. Pulmonary oedema associated with airway obstruction. *Can J Anaesth* 1990; **37**: 210–218.

59 Papadimos T, Vandse R, Kothari D, Tripathi R, Lopez L, Stawicki SA. Negative pressure pulmonary edema with laryngeal mask airway use: Recognition, pathophysiology and treatment modalities. *Int J Crit Illn Inj Sci* 2012; **2**: 98.

**FIGURE/VIDEO CAPTIONS** *figures should NOT be embedded in this document*

**OWNER'S PERSPECTIVE** *Optional*

**Copyright Statement**

1  
2  
3  
4  
5  
6  
7  
8  
9  
10  
11  
12  
13  
14  
15  
16  
17  
18  
19  
20  
21  
22  
23  
24  
25  
26  
27  
28  
29  
30  
31  
32  
33  
34  
35  
36  
37  
38  
39  
40  
41  
42  
43  
44  
45  
46  
47  
48  
49  
50

I, *Luis Filipe Louro*, The Corresponding Author, has the right to assign on behalf of all authors and does assign on behalf of all authors, a full assignment of all intellectual property rights for all content within the submitted case report (other than as agreed with the BMJ Publishing Group Ltd and the British Veterinary Association) ("BMJ" and "BVA") in any media known now or created in the future, and permits this case report (if accepted) to be published on Veterinary Record Case Reports and to be fully exploited within the remit of the assignment as set out in the assignment which has been read <http://journals.bmj.com/site/misc/vetreccrcopyright.pdf>

**Date: 04/07/2019**

---

**PLEASE SAVE YOUR TEMPLATE WITH THE FOLLOWING FORMAT:**

Corresponding author's last name and date of submission, eg,  
Smith\_June\_2017.doc

45  
46  
47  
48  
49  
50  
51  
52  
53  
54  
55  
56  
57  
58  
59  
60